

Reoperations in Anorectal Malformation

Alberto Peña, MD

The 65th Workshop for the Surgical Treatment of Colorectal Problems in Children



Children's Hospital Colorado
Here, it's different.™

INTERNATIONAL CENTER FOR
**COLORECTAL AND
UROGENITAL CARE**

Patients with Fecal Incontinence

EVALUATION

History, physical exam,
Sacral and Spinal films

Kidney Ultrasound

Contrast enema

M. R. I.

Not trainable

(Poor prognosis)

Candidates
for secondary
pull-through

Pseudo-
incontinent

Candidates for
sigmoid resection

Trainable



**Not trainable
(Poor prognosis)**



**Bowel
Management**

**Candidates
for secondary
pull-through**



Reoperation

**Pseudo-
incontinent**



**Laxatives
and/or
sigmoid
resection**

Trainable



**Advice
for
training**



Reoperations for Fecal Incontinence



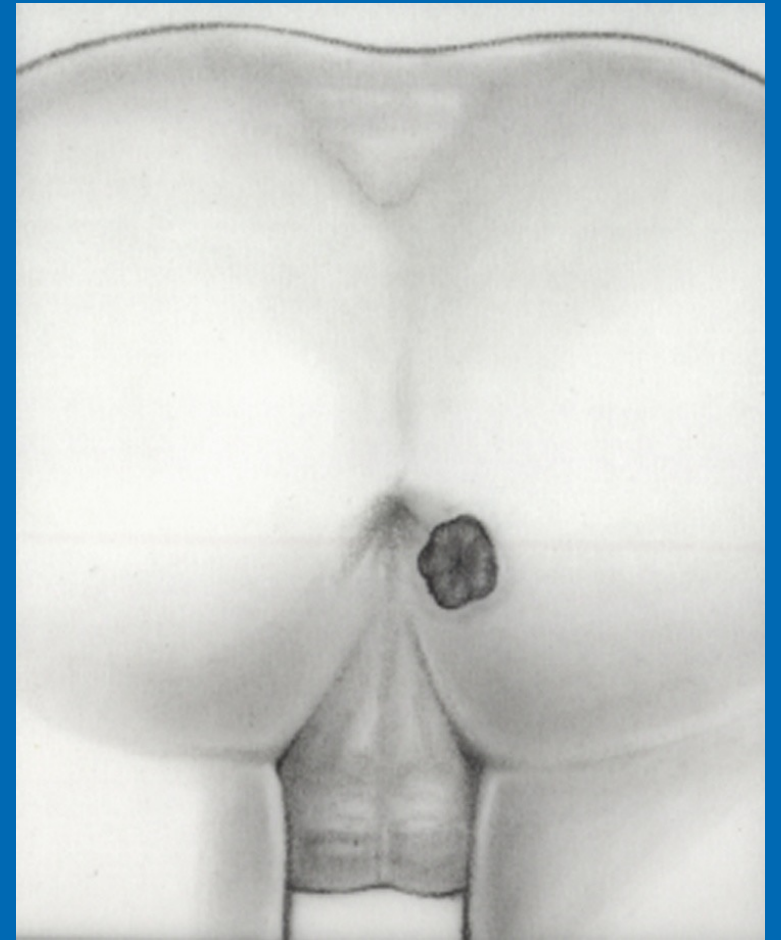
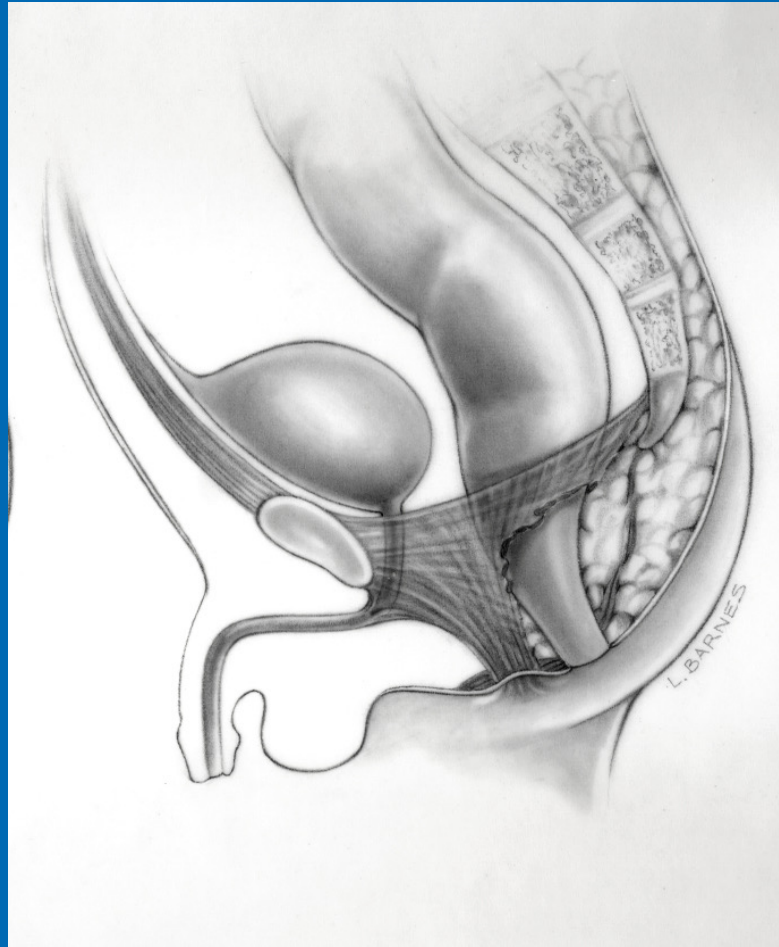
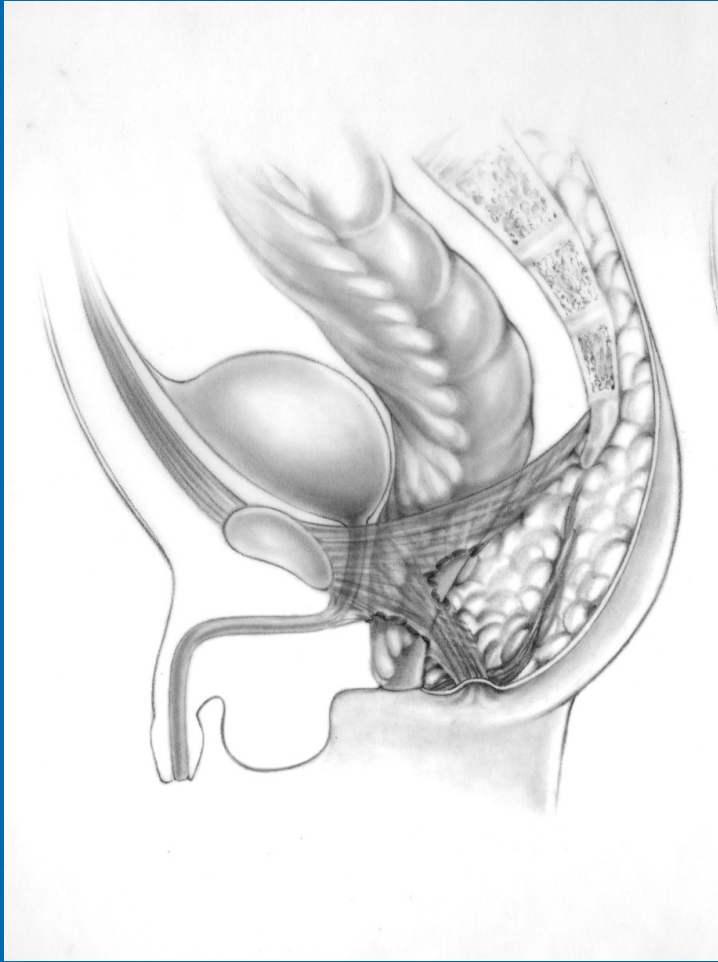
Children's Hospital Colorado
Here, it's different.™

INTERNATIONAL CENTER FOR
**COLORECTAL AND
UROGENITAL CARE**

Candidates for a Re-operation

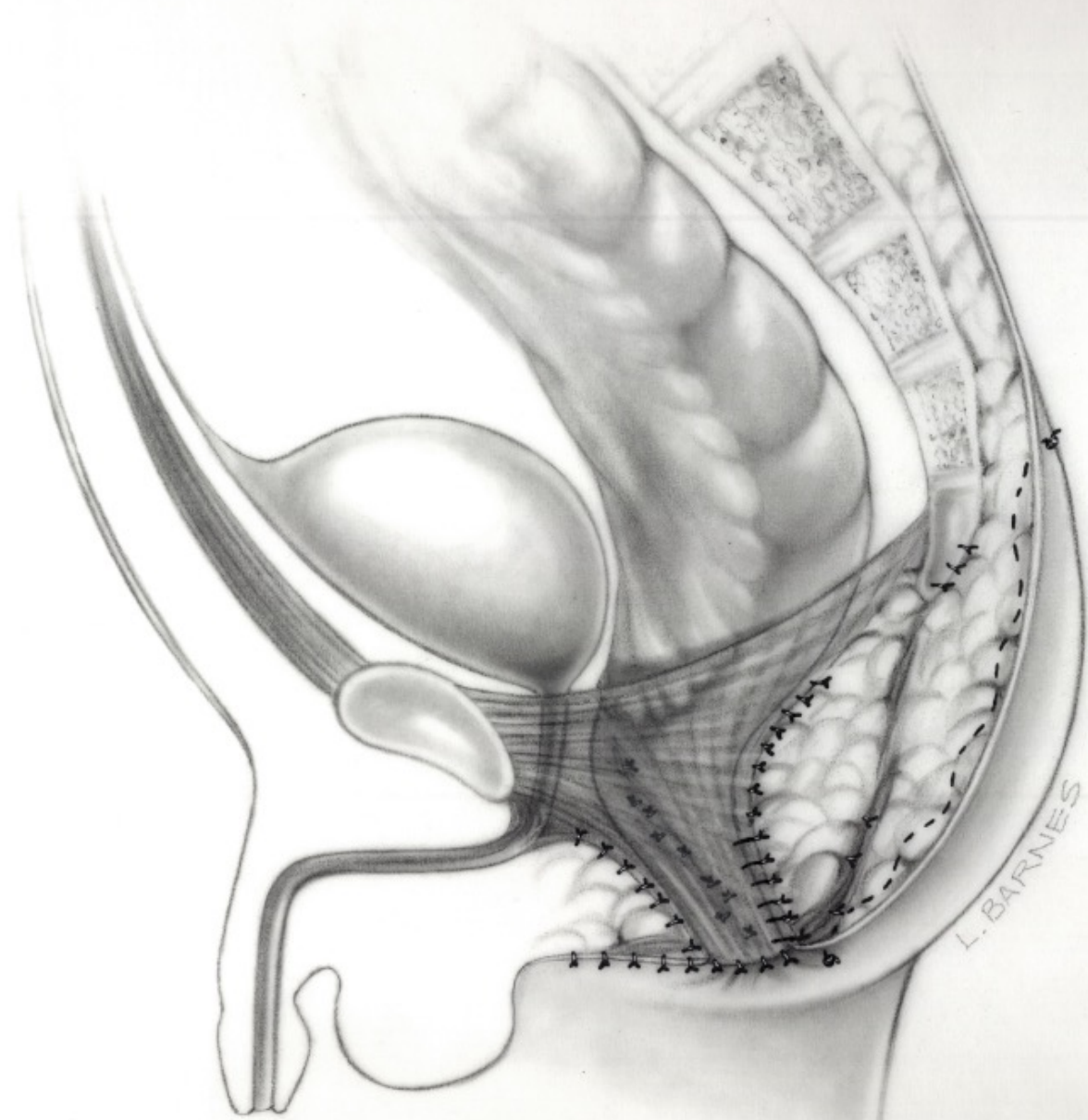
- Born with a ‘good’ defect
- Good sacrum
- Good sphincter
- Completely mislocated rectum





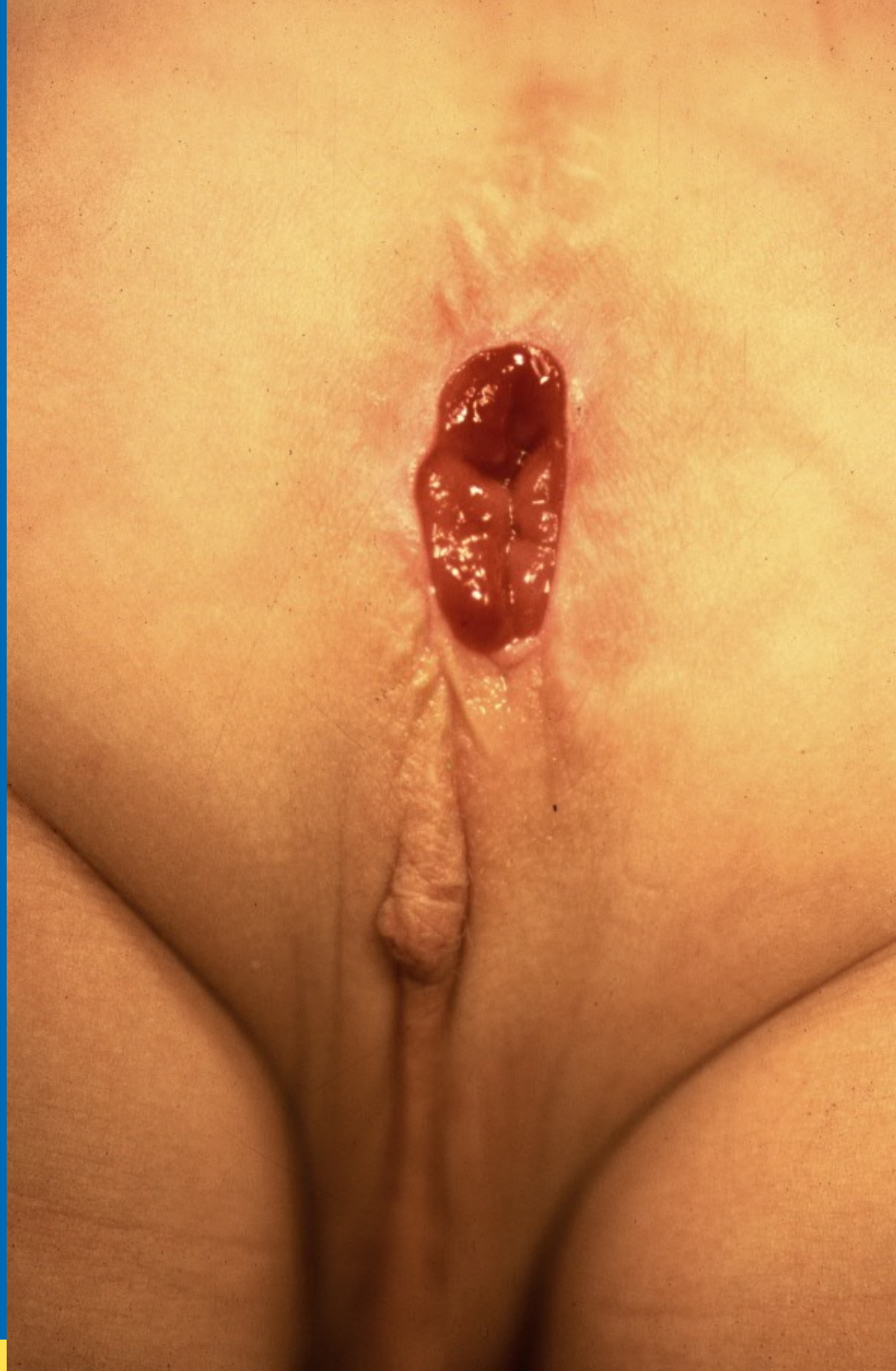Children's Hospital Colorado
Here, it's different.™

INTERNATIONAL CENTER FOR
**COLORECTAL AND
UROGENITAL CARE**



Children's Hospital Colorado
Here, it's different.™

INTERNATIONAL CENTER FOR
**COLORECTAL AND
UROGENITAL CARE**



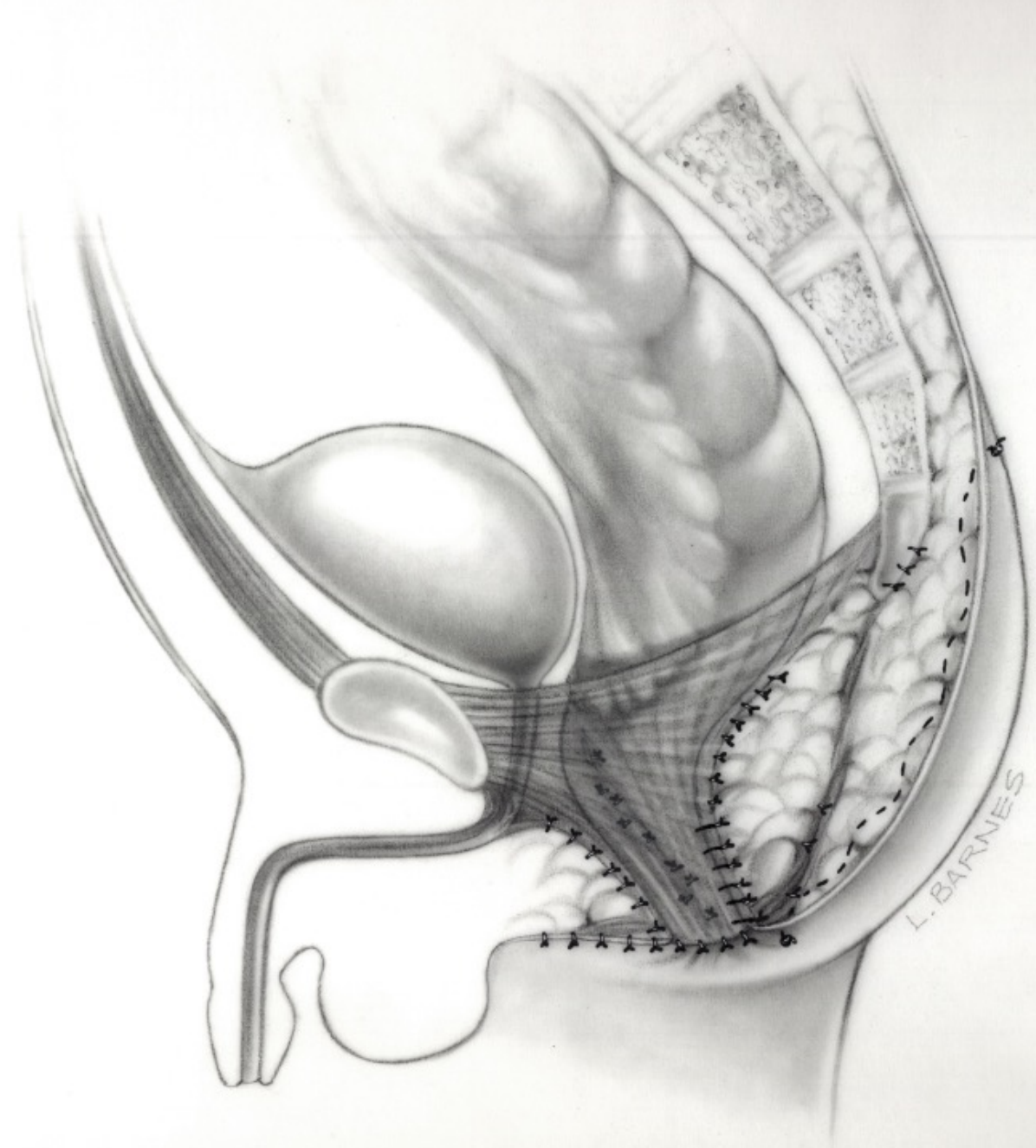
Children's Hospital Colorado
Here, it's different.™

INTERNATIONAL CENTER FOR
**COLORECTAL AND
UROGENITAL CARE**



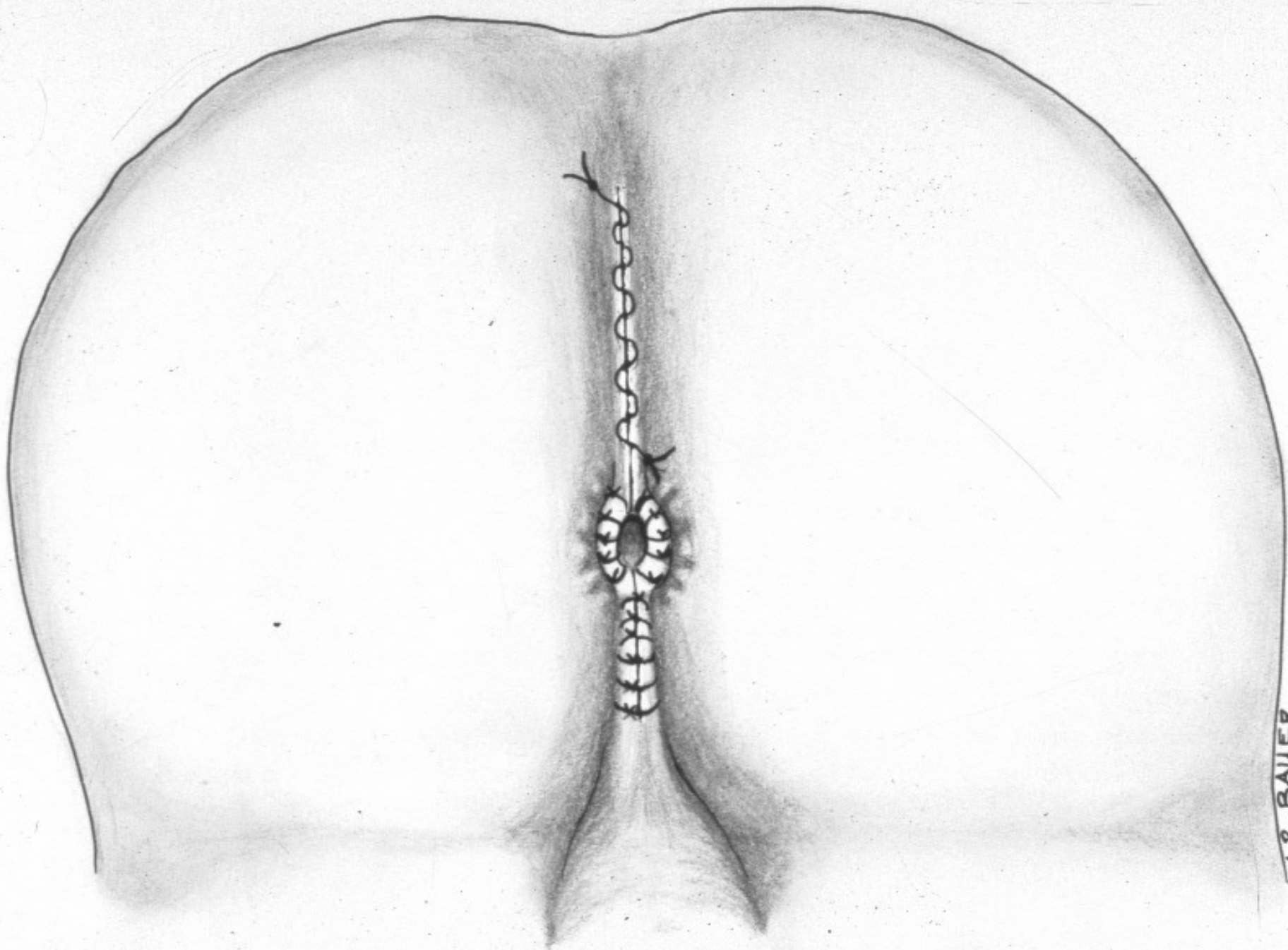
Children's Hospital Colorado
Here, it's different.™

INTERNATIONAL CENTER FOR
**COLORECTAL AND
UROGENITAL CARE**



Children's Hospital Colorado
Here, it's different.™

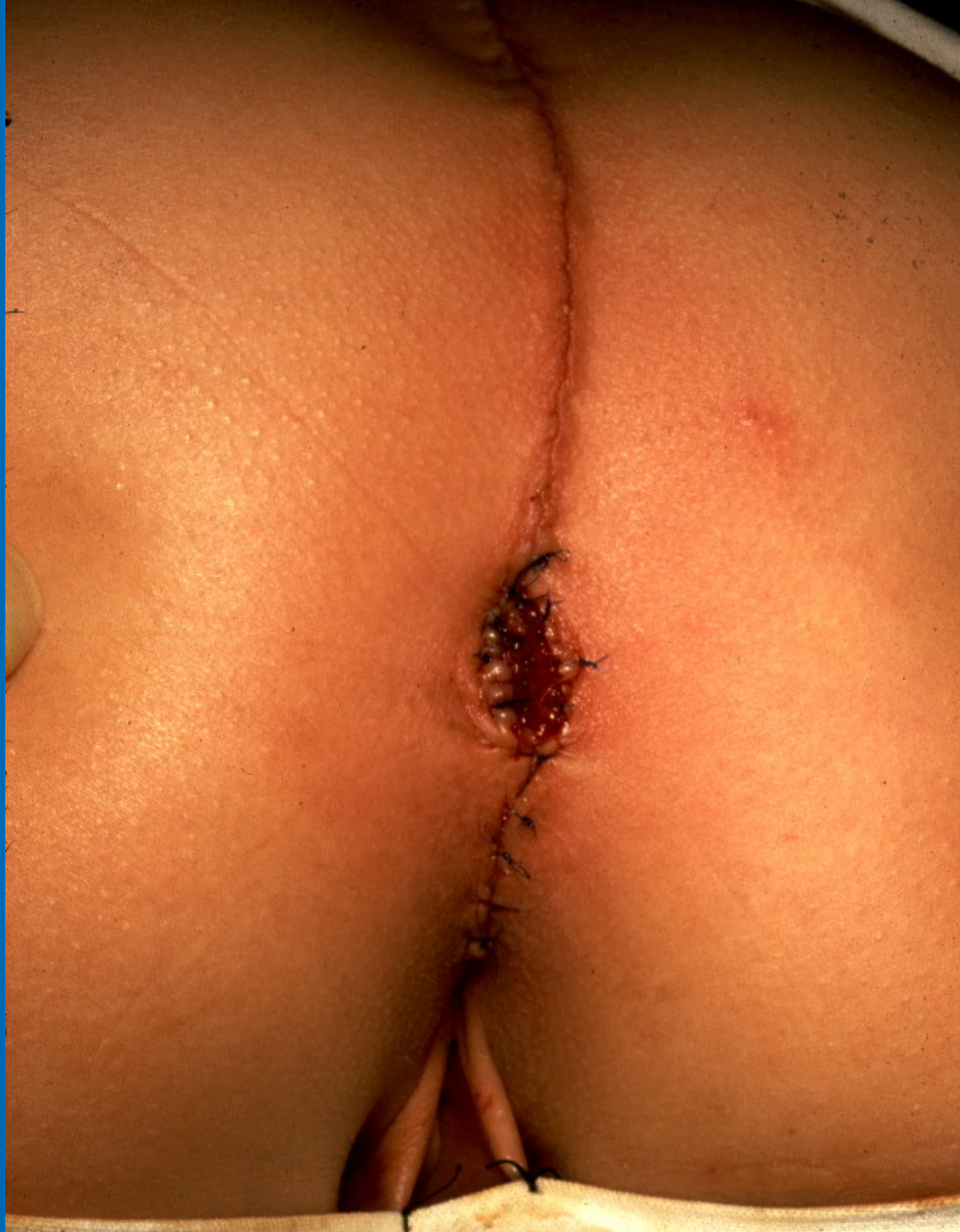INTERNATIONAL CENTER FOR
**COLORECTAL AND
UROGENITAL CARE**



K.R. BAUER



CH
He



Children's Hospital Colorado
Here, it's different.™

INTERNATIONAL CENTER FOR
**COLORECTAL AND
UROGENITAL CARE**

Reoperations for Other Reasons (Catastrophes)



Children's Hospital Colorado
Here, it's different.™

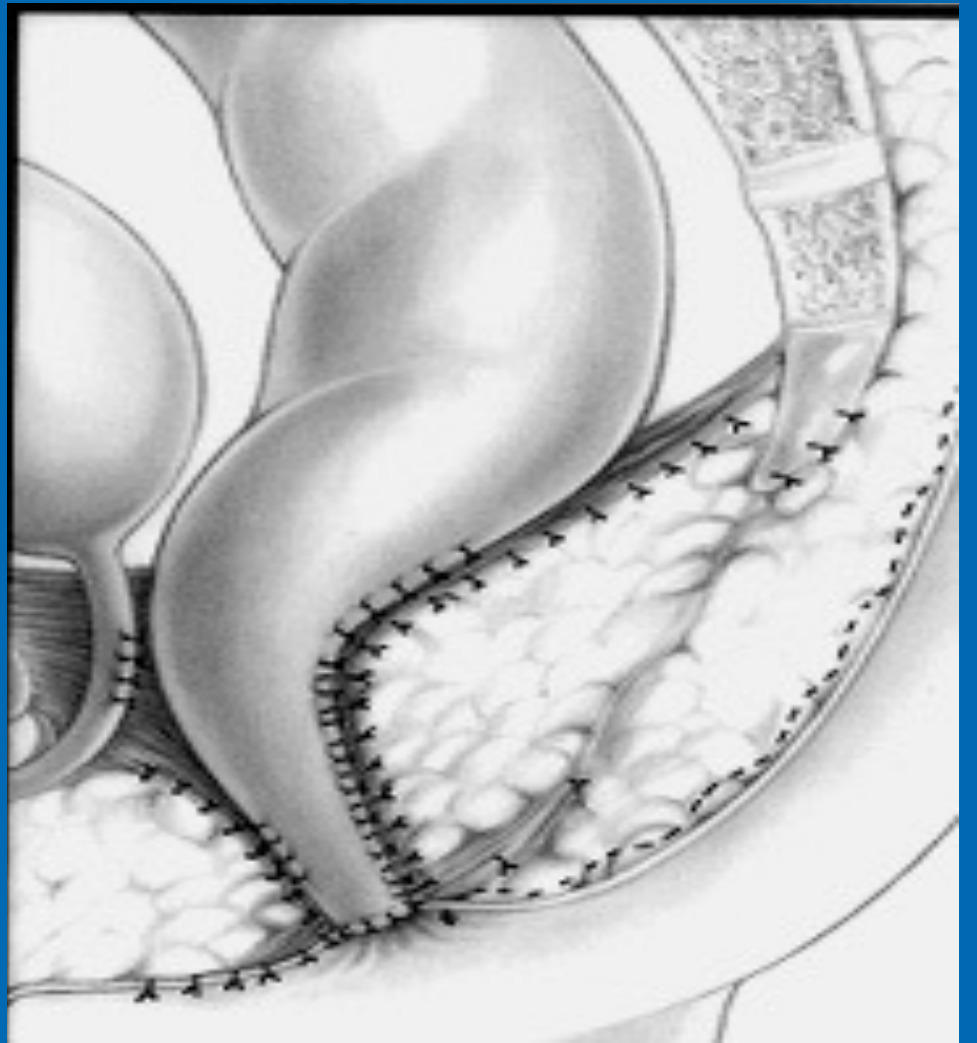
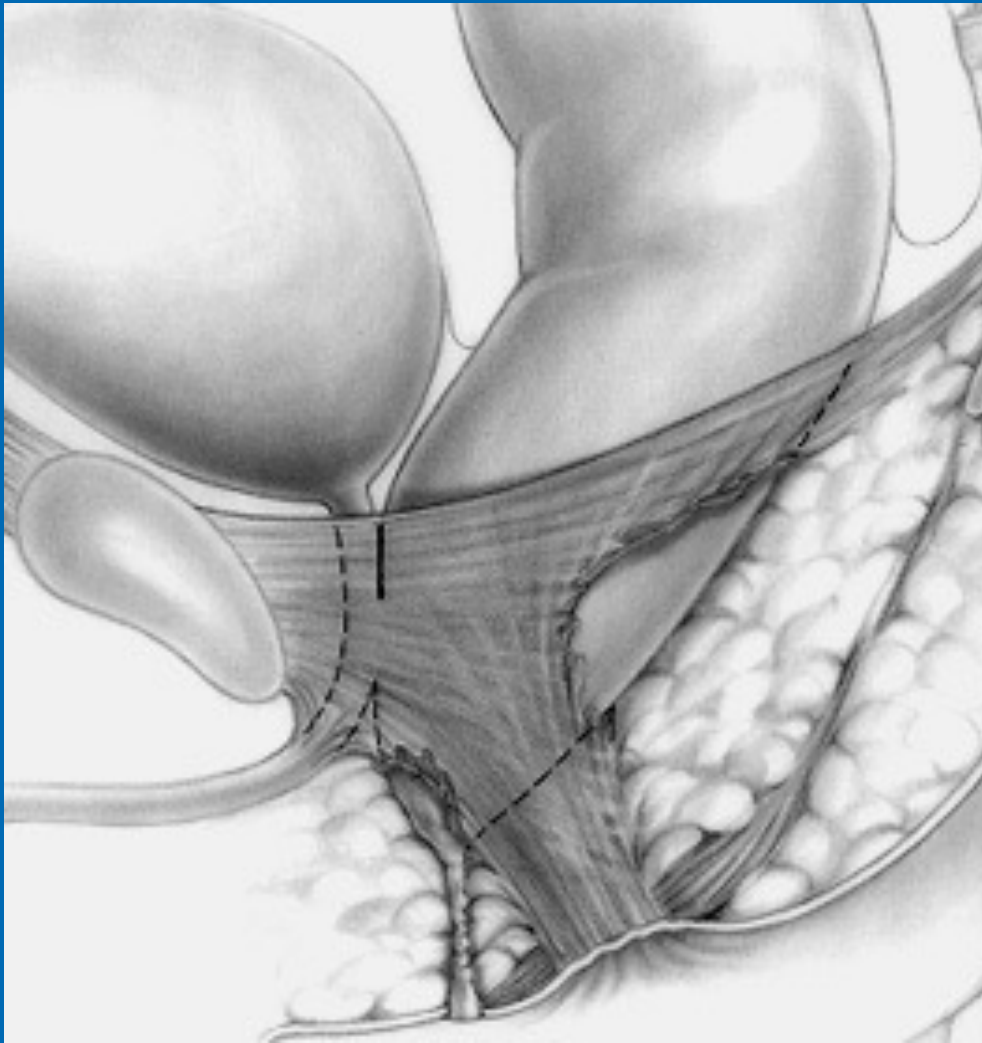INTERNATIONAL CENTER FOR
**COLORECTAL AND
UROGENITAL CARE**

Recto-urinary Fistulae

Males (ARM)

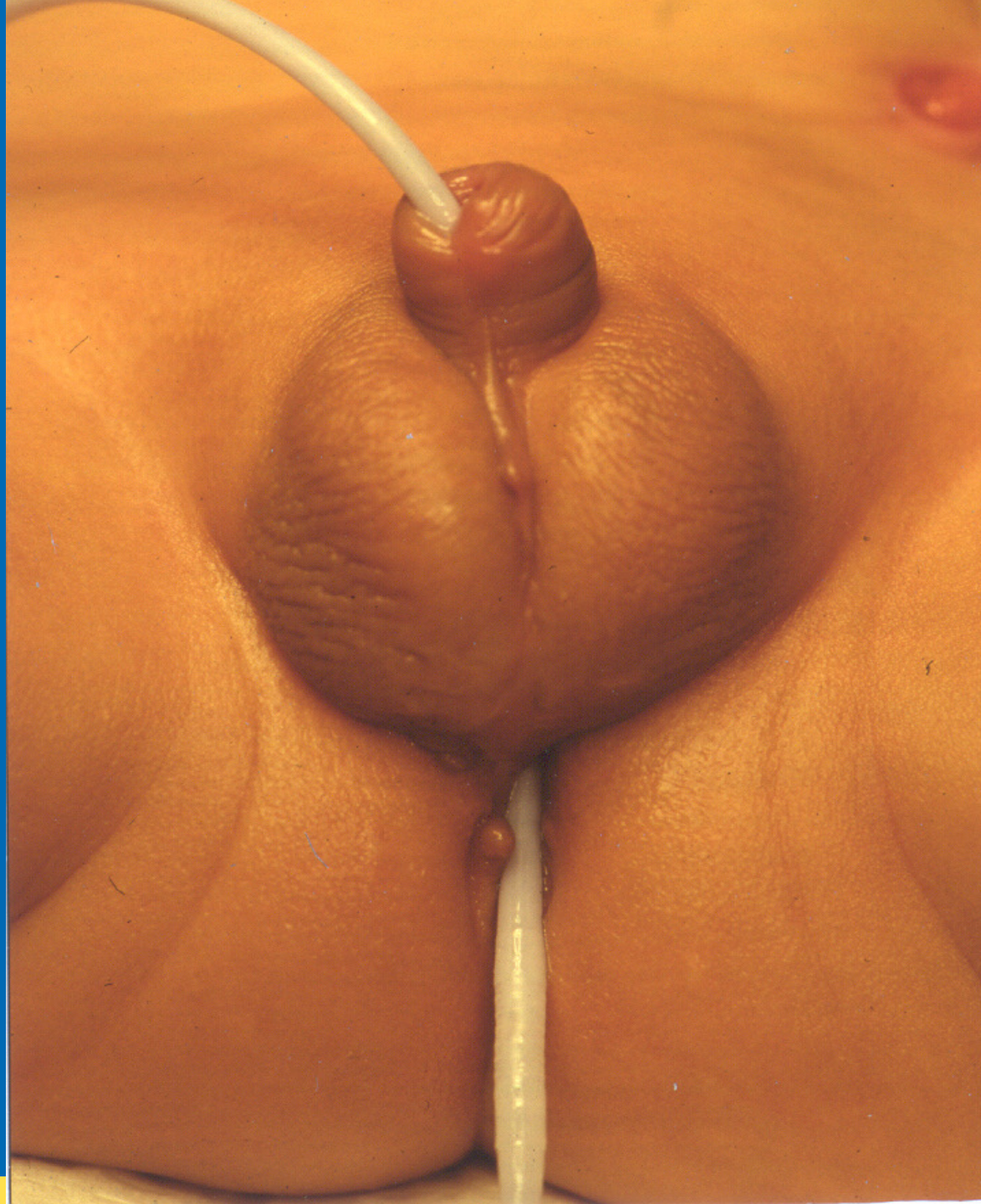Persistent	12
Recurrent	10
Acquired	3
Recto-diverticulum	4
	<hr/>
	29





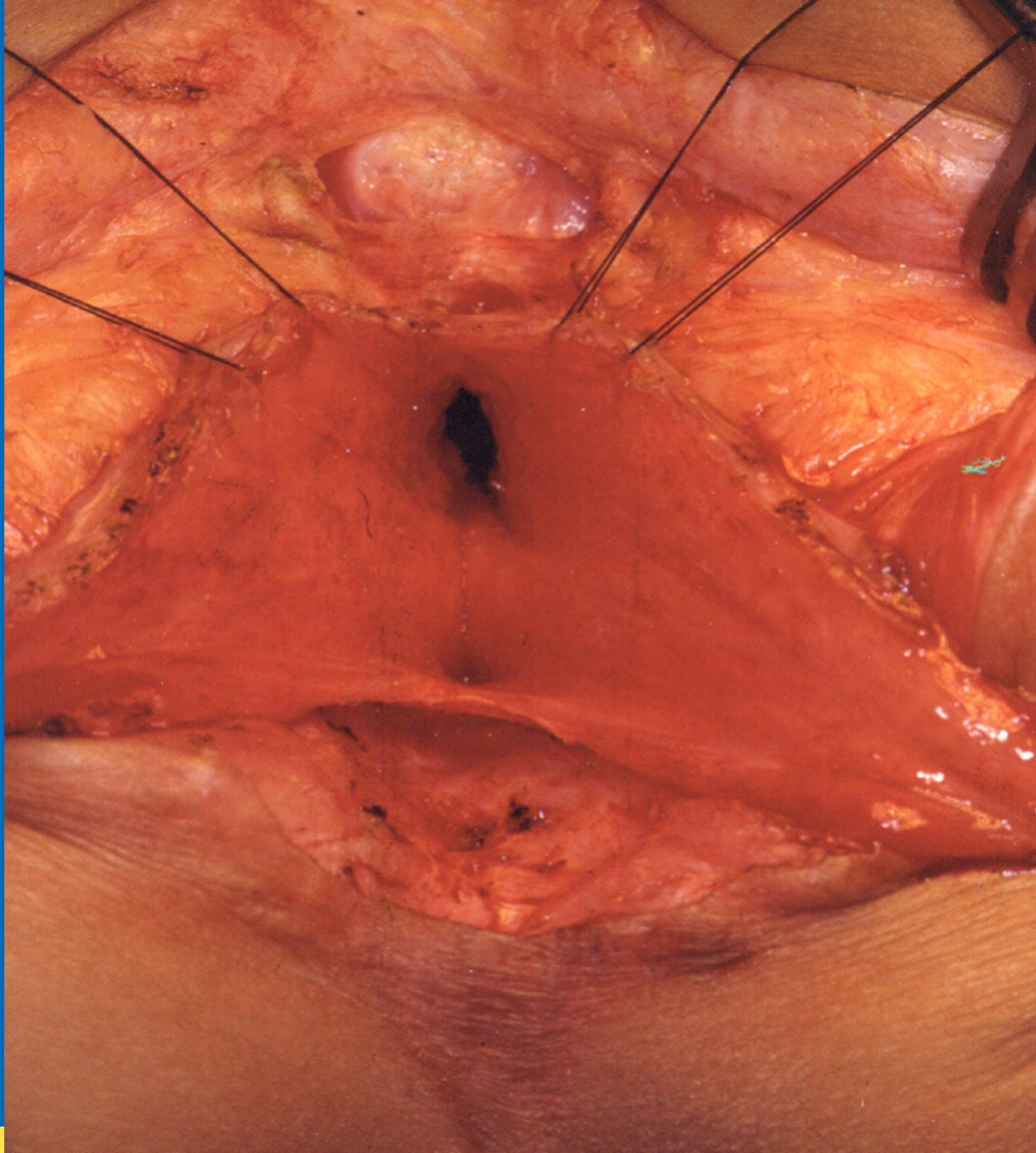
Children's Hospital Colorado
Here, it's different.™

INTERNATIONAL CENTER FOR
**COLORECTAL AND
UROGENITAL CARE**



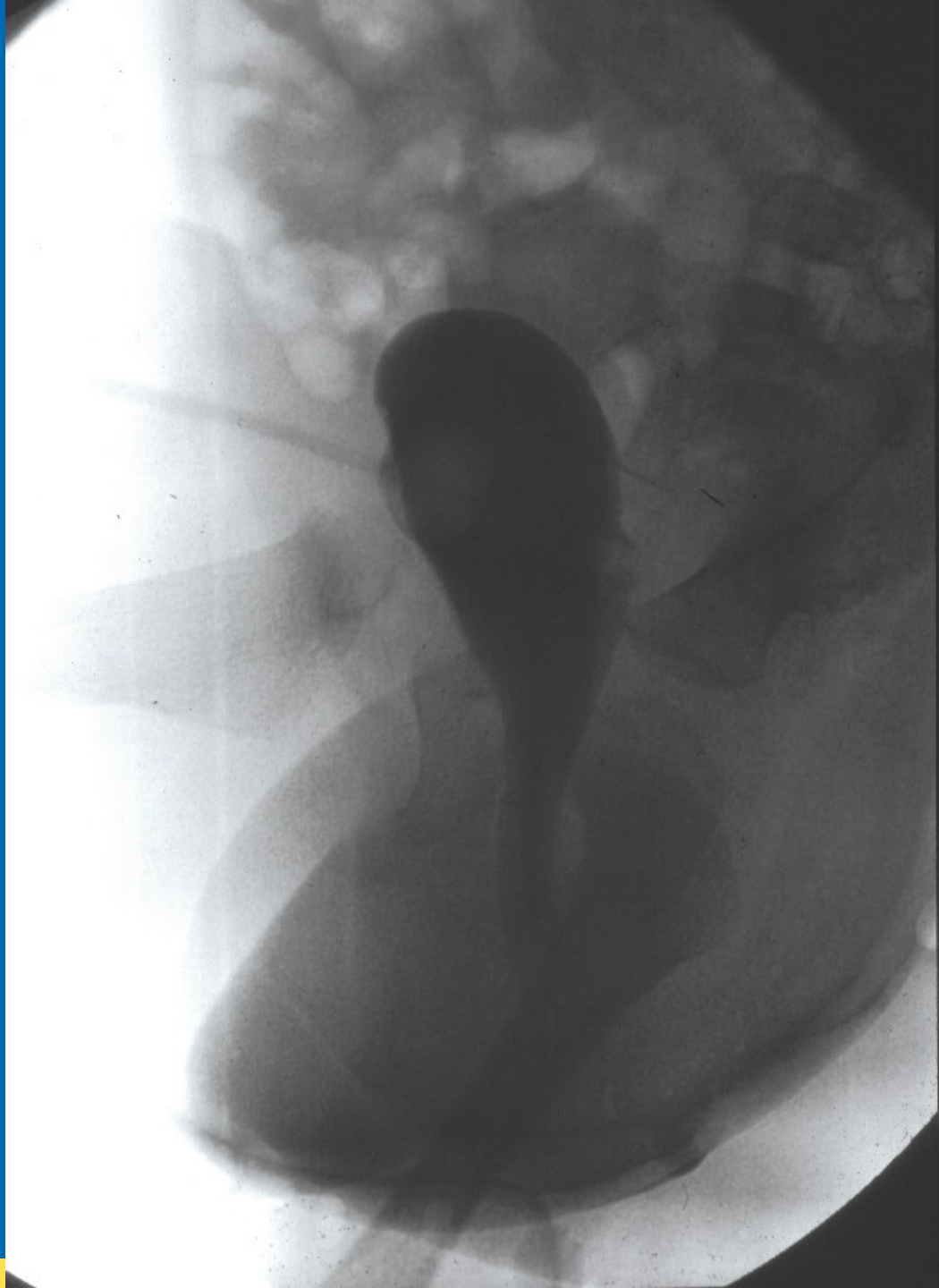Children's Hospital Colorado
Here, it's different.™

INTERNATIONAL CENTER FOR
**COLORECTAL AND
UROGENITAL CARE**



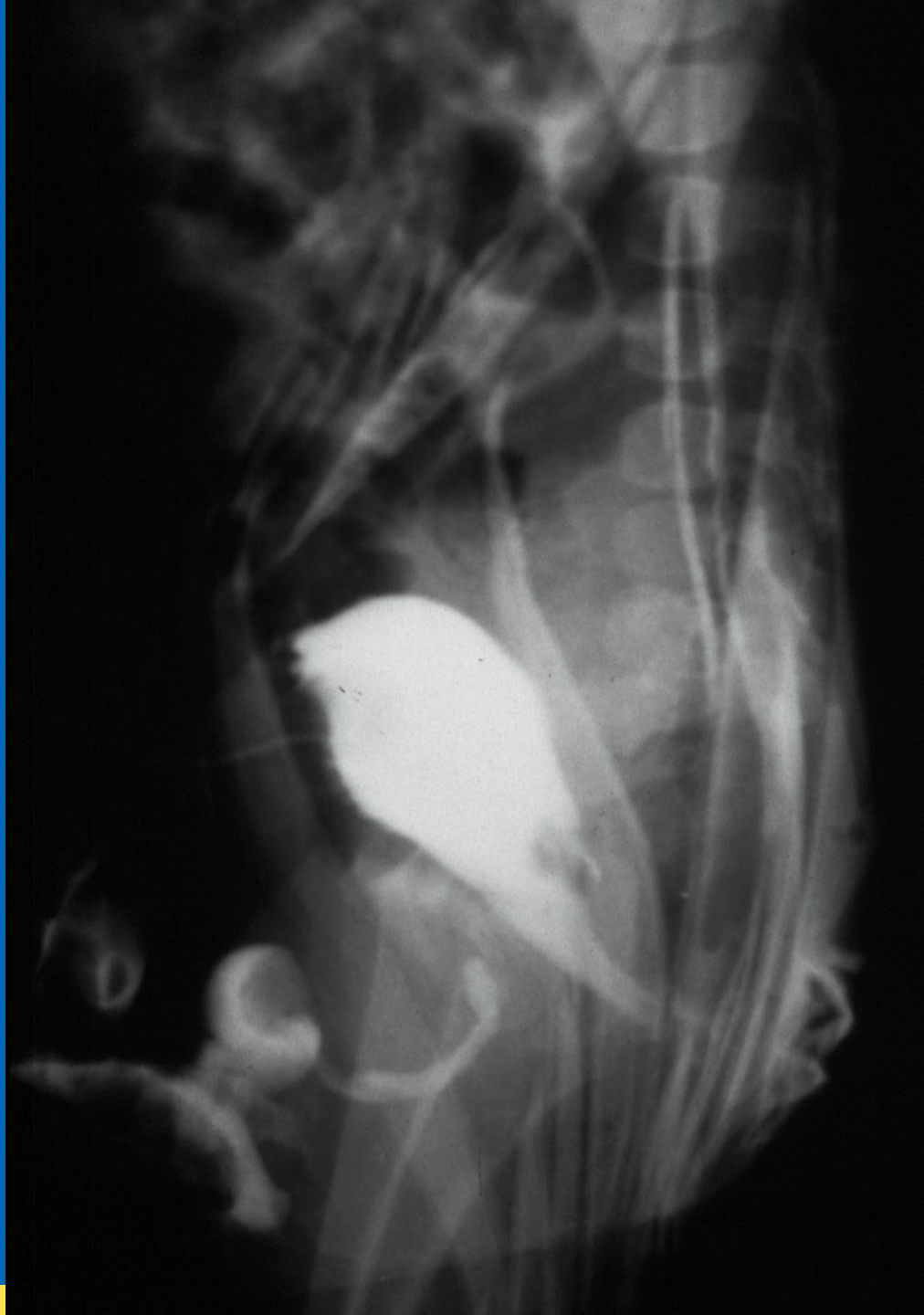
Children's Hospital Colorado
Here, it's different.™

INTERNATIONAL CENTER FOR
**COLORECTAL AND
UROGENITAL CARE**



Children's Hospital Colorado
Here, it's different.™

INTERNATIONAL CENTER FOR
**COLORECTAL AND
UROGENITAL CARE**



Children's Hospital Colorado
Here, it's different.™

INTERNATIONAL CENTER FOR
**COLORECTAL AND
UROGENITAL CARE**

Urethral Injuries

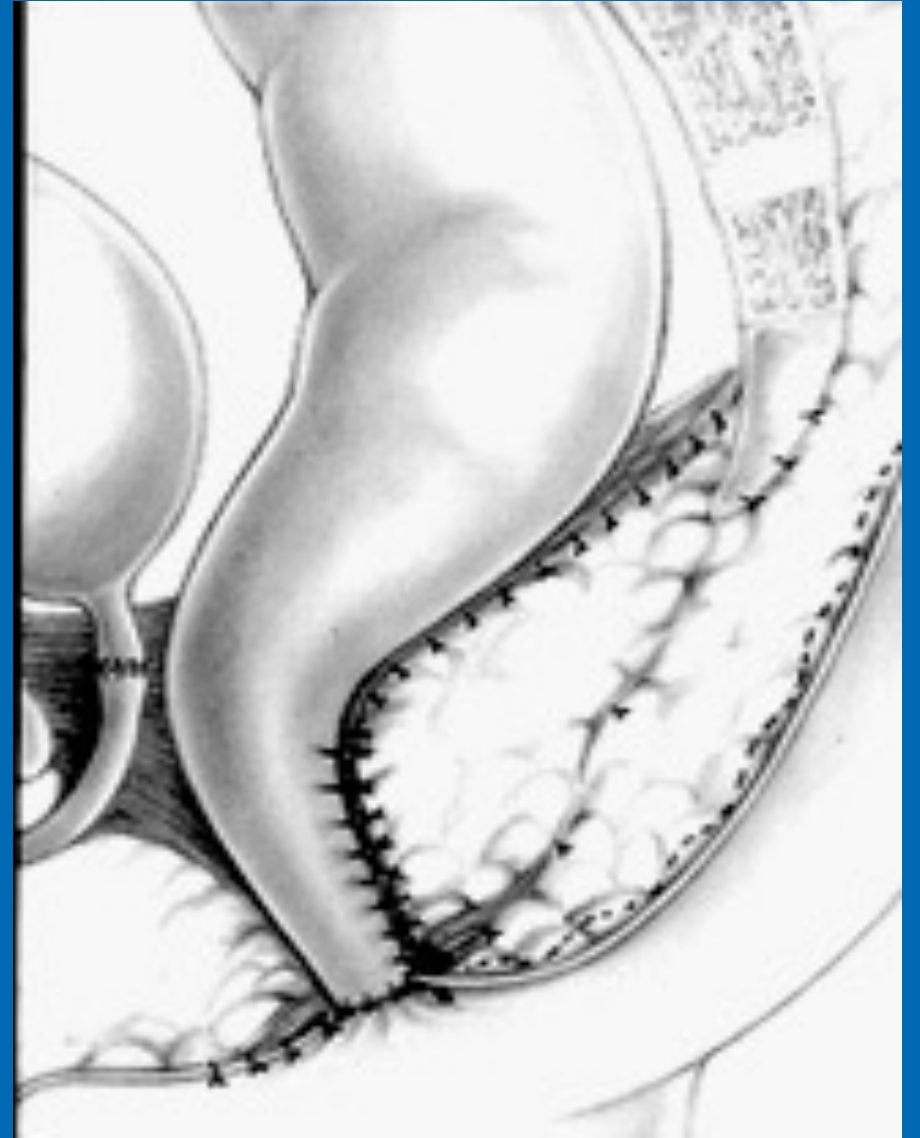

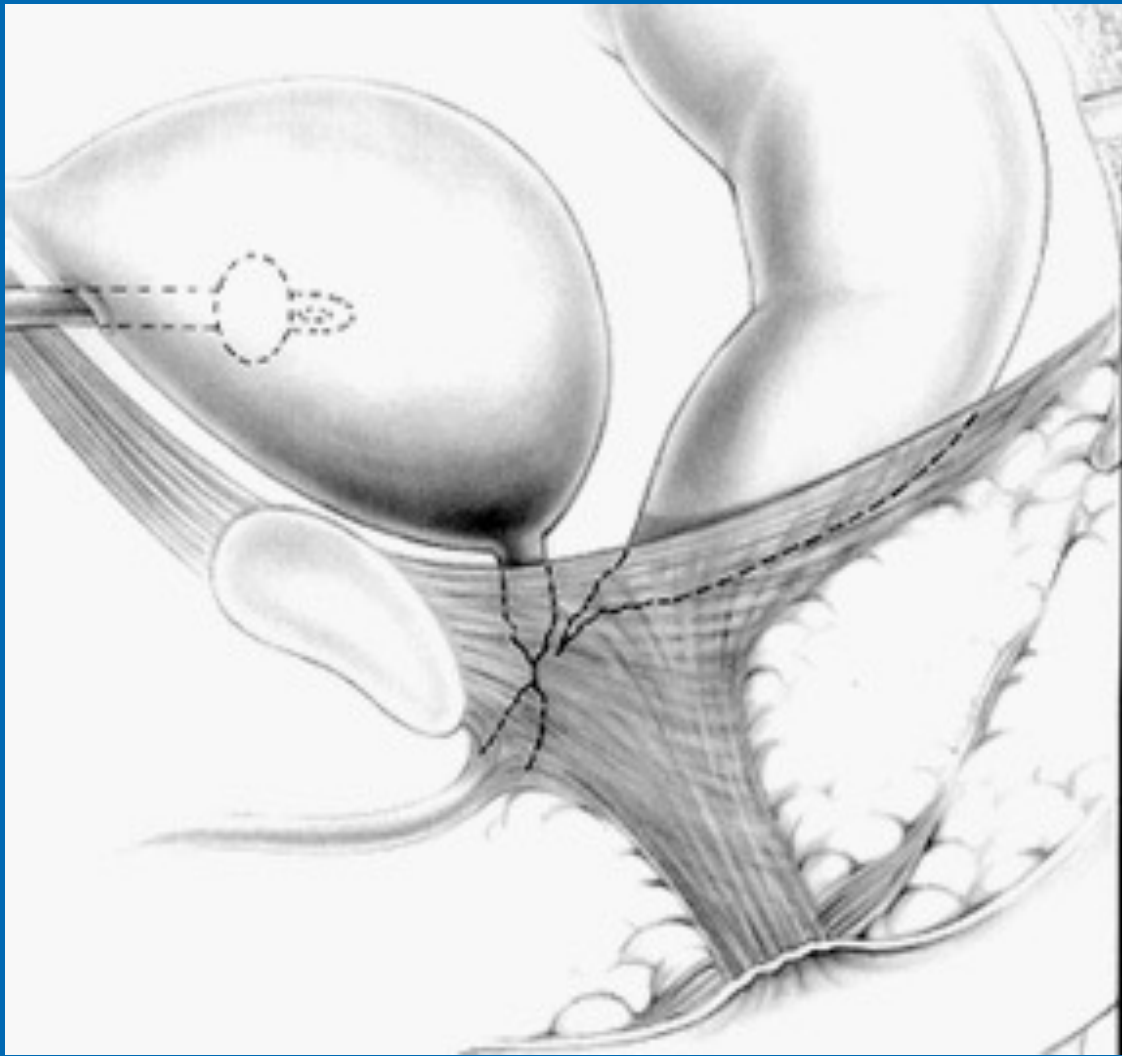
Group B

19 cases of stenosis or acquired
atresia - 4.4%



Children's Hospital Colorado
Here, it's different.™

INTERNATIONAL CENTER FOR
**COLORECTAL AND
UROGENITAL CARE**



Children's Hospital Colorado
Here, it's different.™

INTERNATIONAL CENTER FOR
**COLORECTAL AND
UROGENITAL CARE**

Posterior Urethral Diverticulum

3 of 432 cases - 5.3%



Children's Hospital Colorado
Here, it's different.™

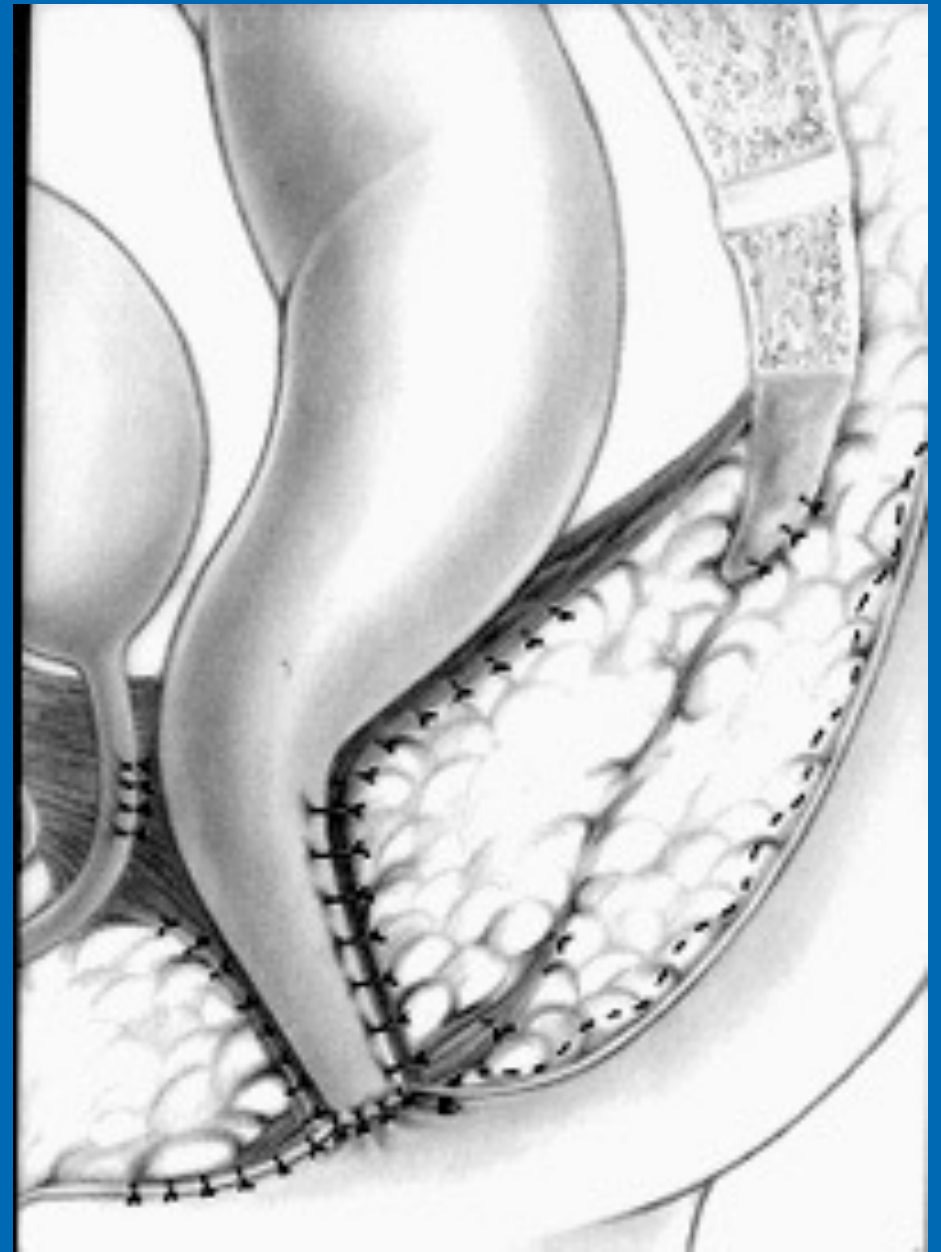

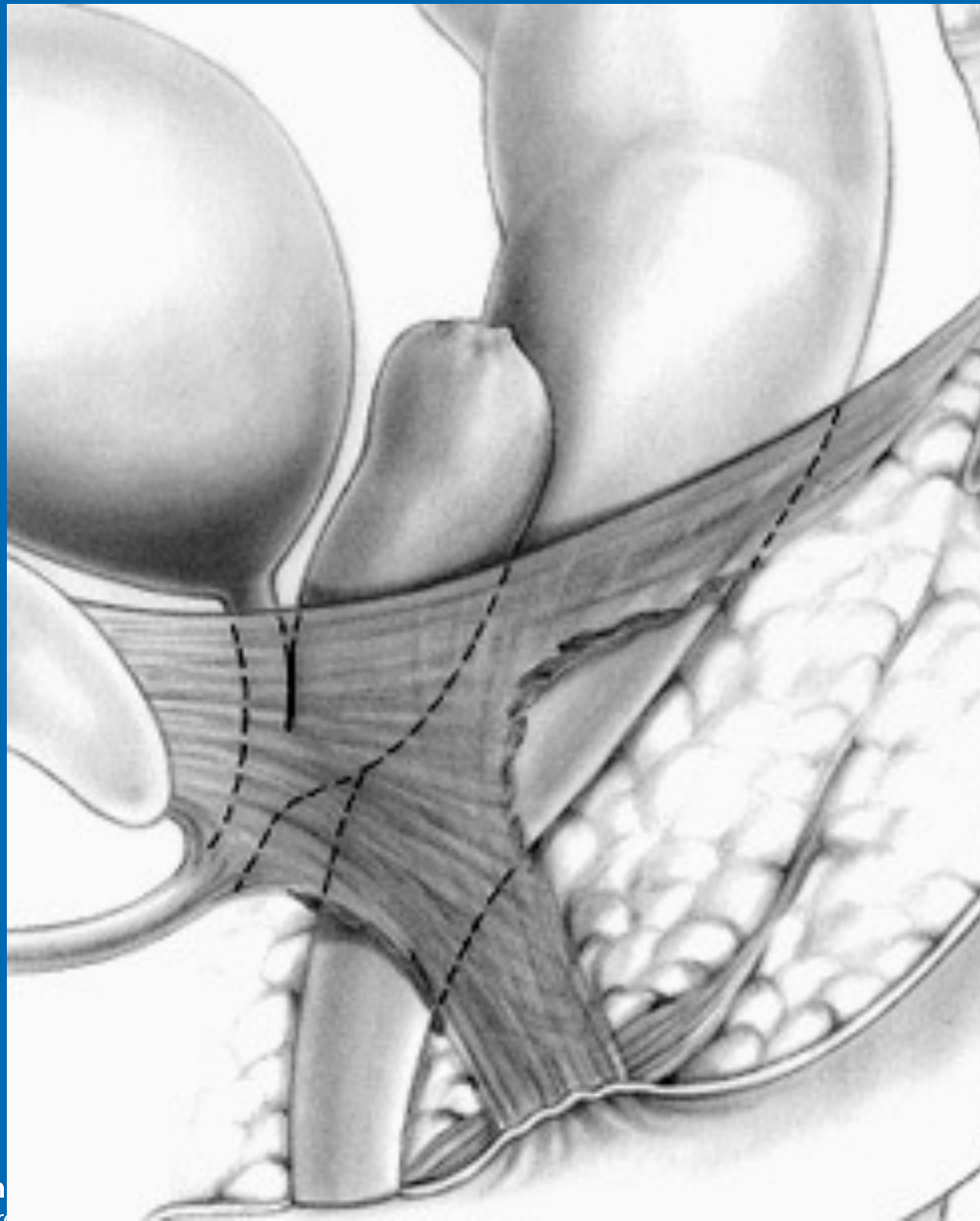
INTERNATIONAL CENTER FOR
**COLORECTAL AND
UROGENITAL CARE**

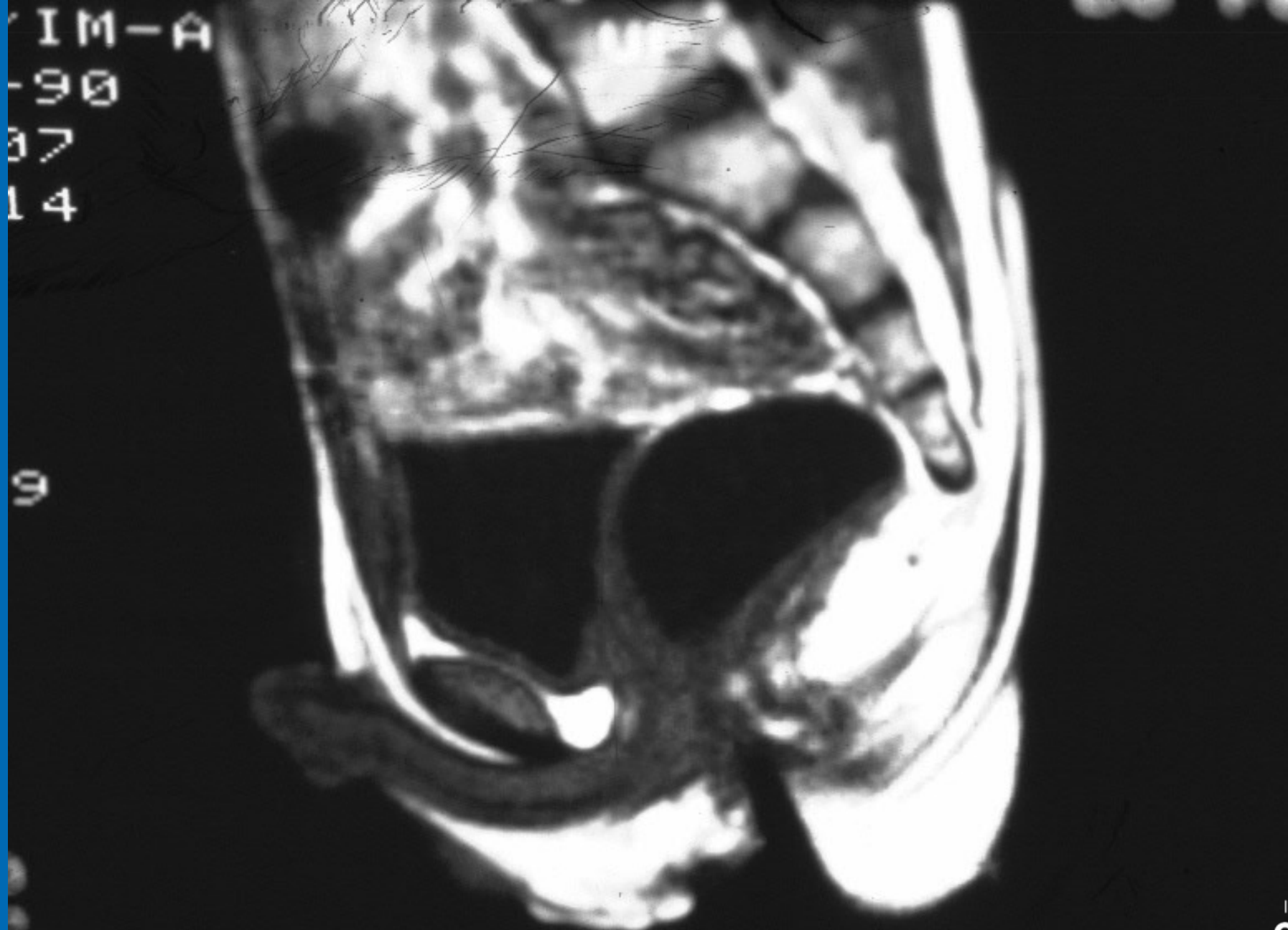
Posterior Urethral Diverticulum After Laparoscopic Repair of an Anorectal Malformation



Children's Hospital Colorado

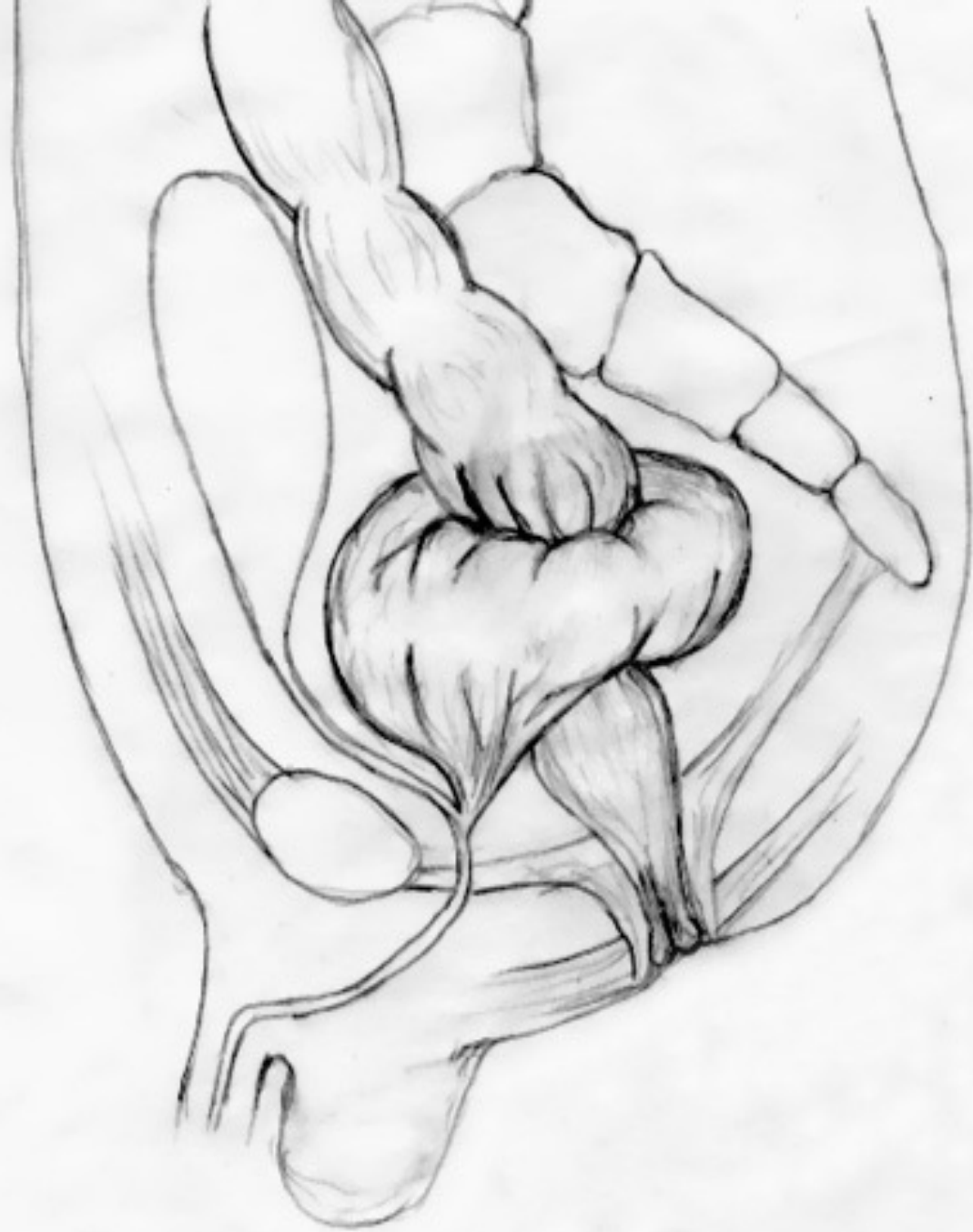® International Center for
Colorectal Care





Children's Hospital Colorado
Here, it's different.™

INTERNATIONAL CENTER FOR
**COLORECTAL AND
UROGENITAL CARE**



GR



Children's Hospital Colorado
Here, it's different.™

INTERNATIONAL CENTER FOR
**COLORECTAL AND
UROGENITAL CARE**

Malignancy

31 yr. Old

Adenocarcinoma in the
diverticulum
(not previously reported)

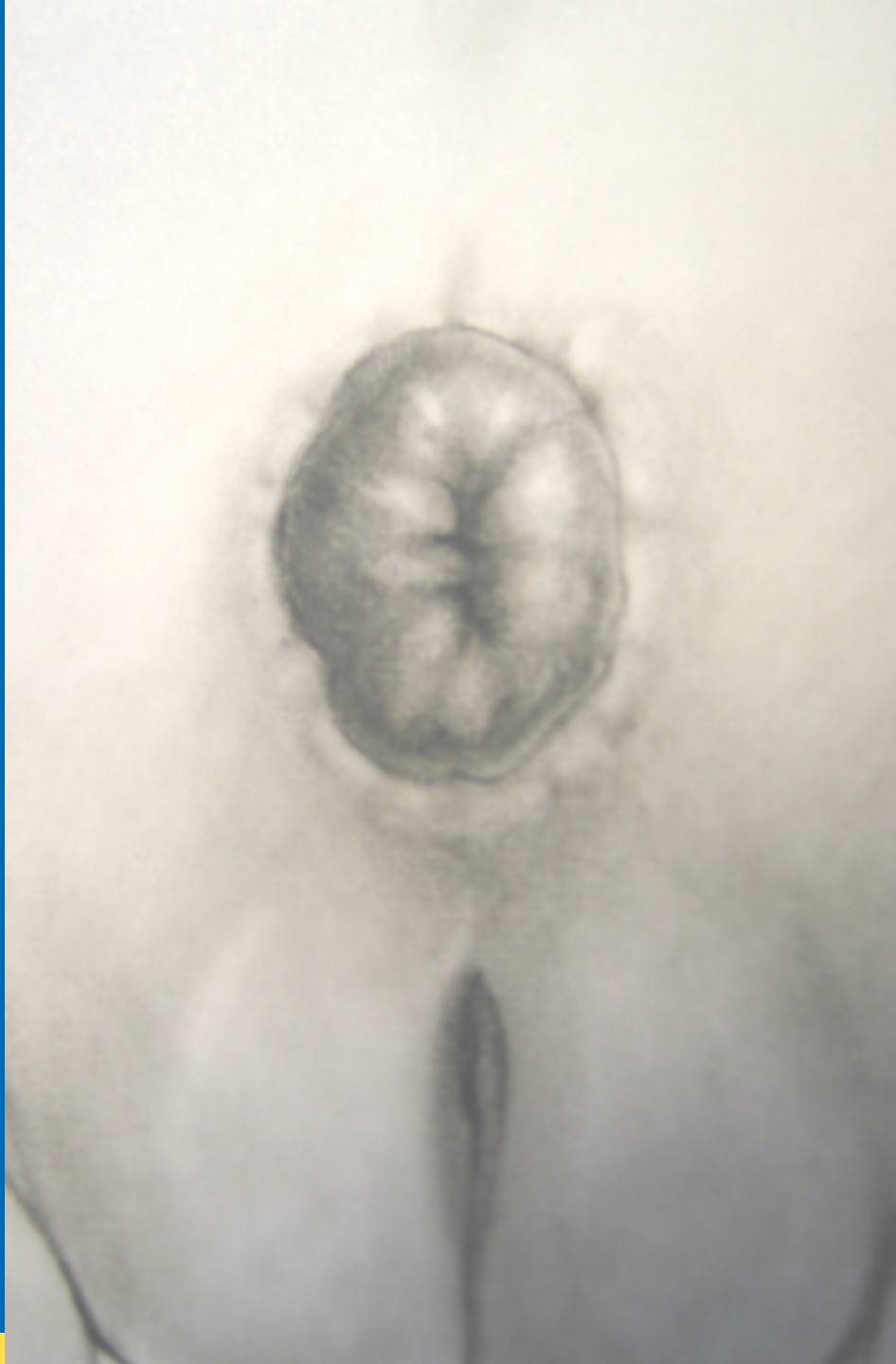


Rectal Prolapse



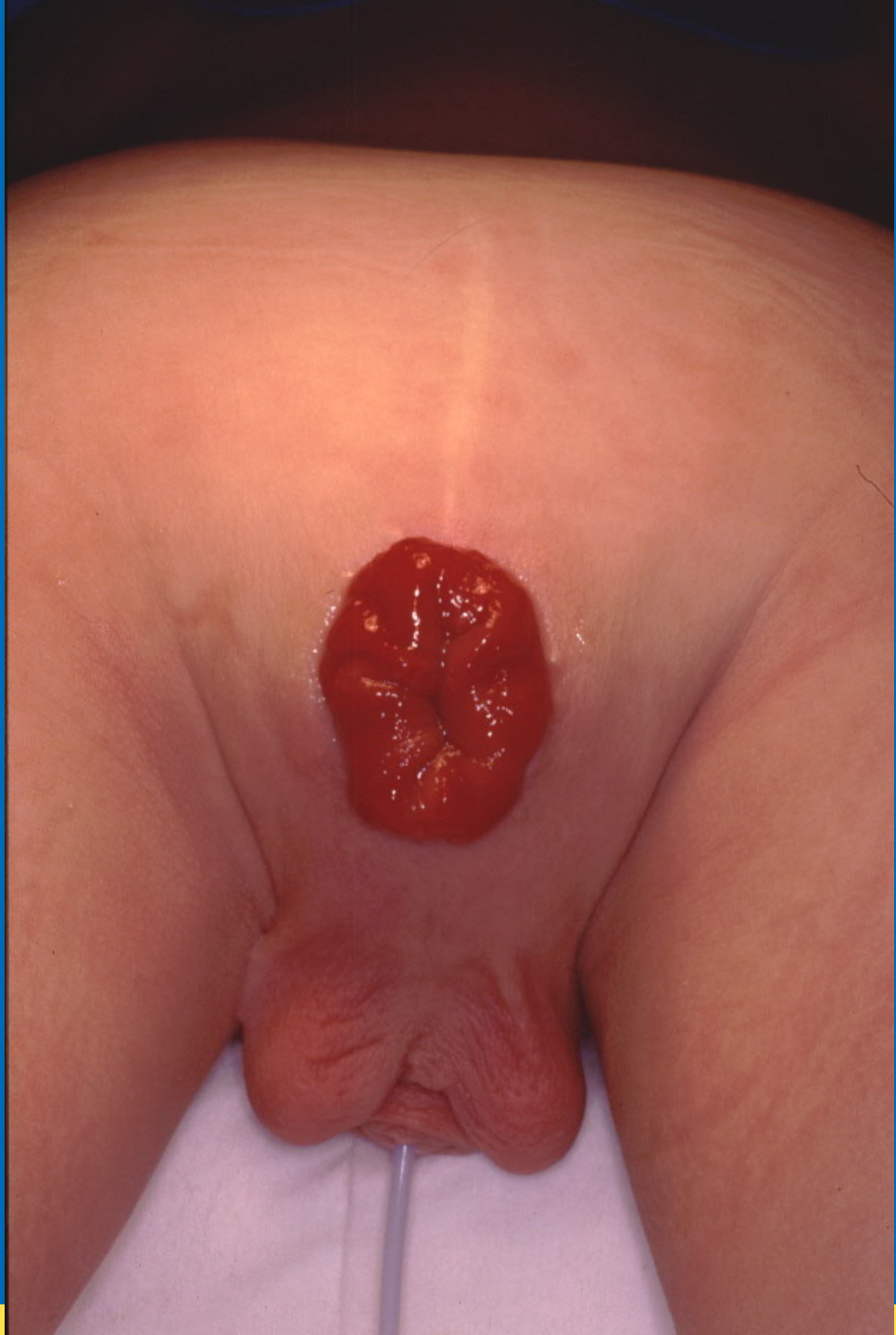Children's Hospital Colorado
Here, it's different.™

INTERNATIONAL CENTER FOR
**COLORECTAL AND
UROGENITAL CARE**



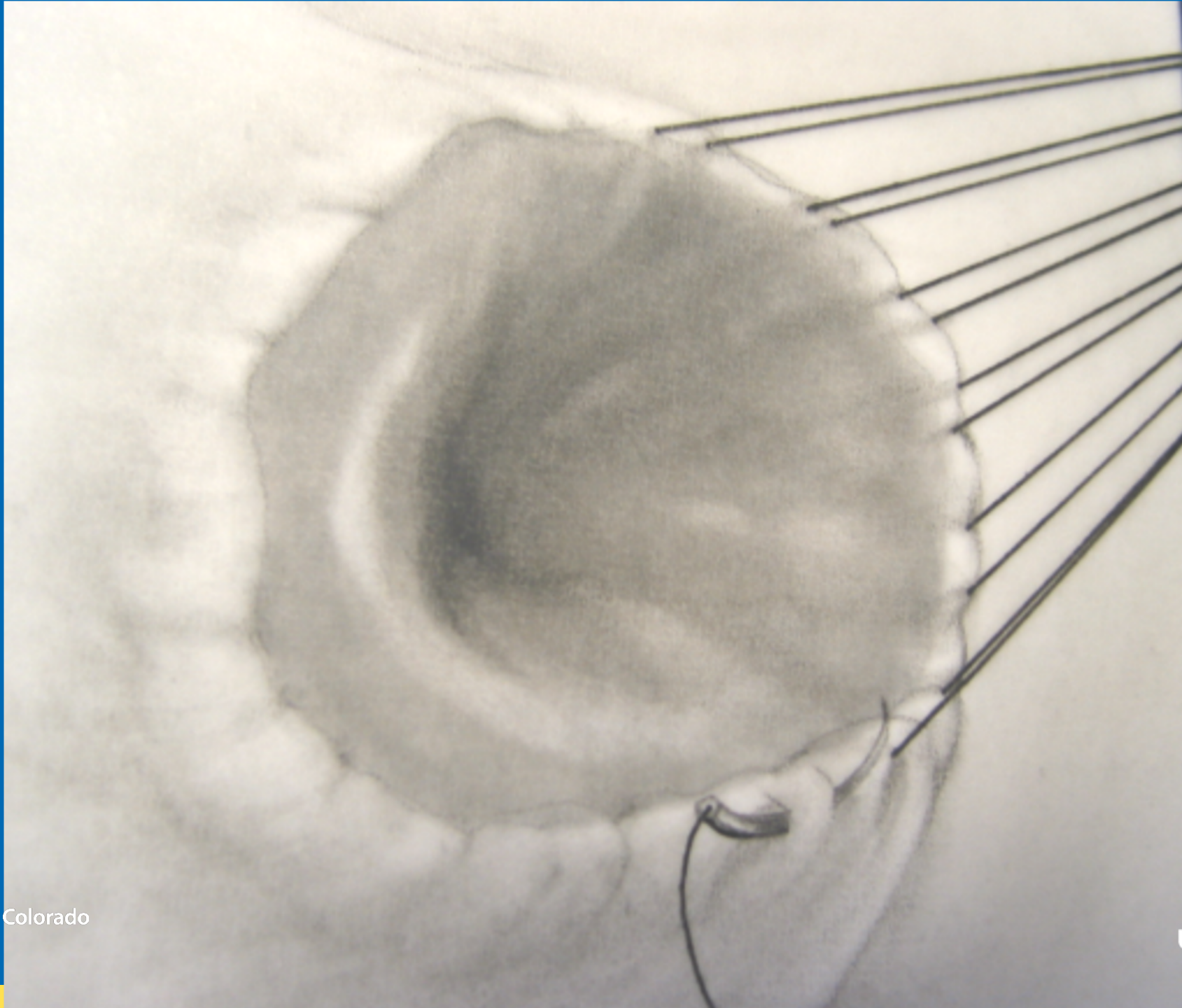
Children's Hospital Colorado
Here, it's different.™

INTERNATIONAL CENTER FOR
**COLORECTAL AND
UROGENITAL CARE**



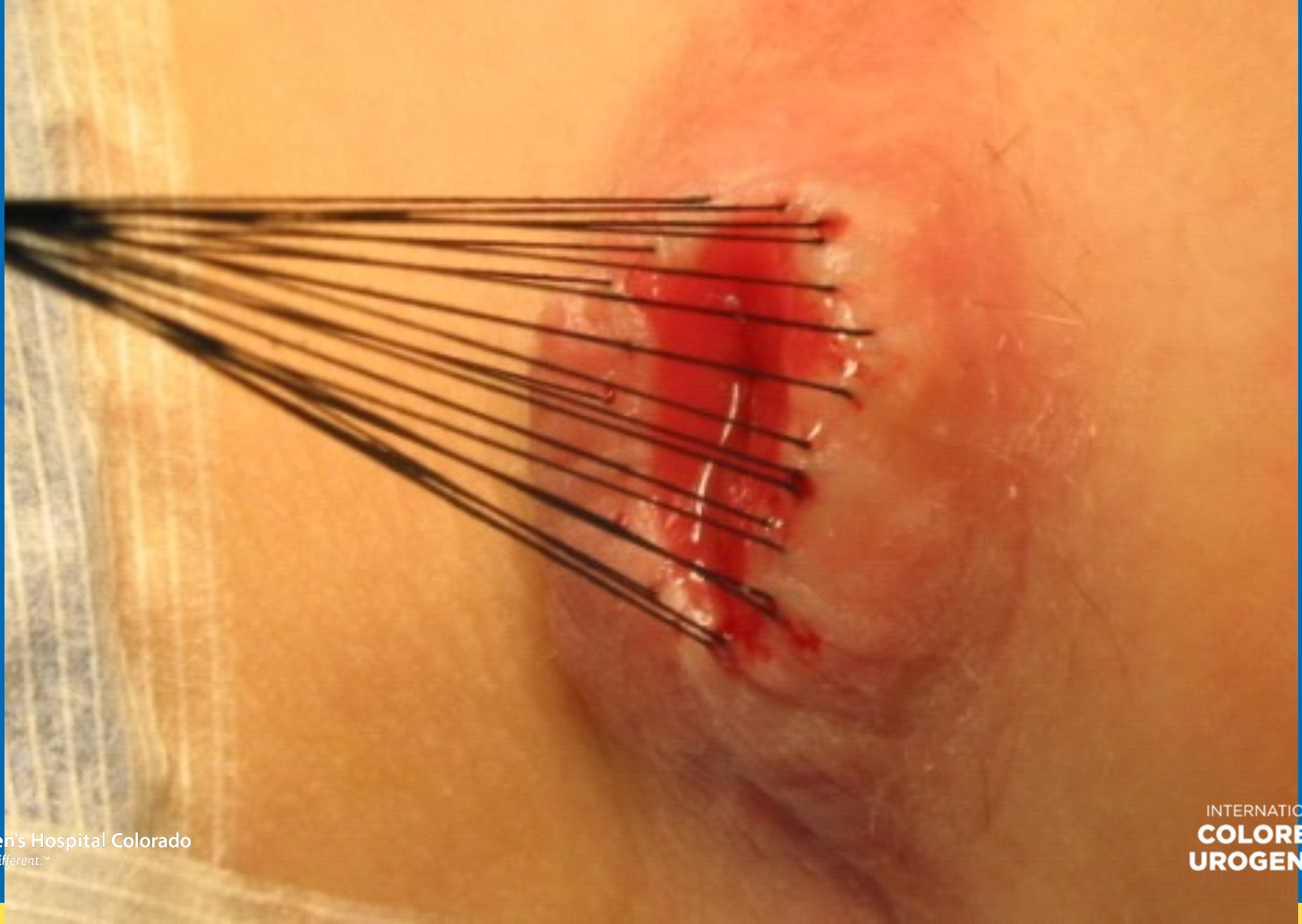
Children's Hospital Colorado
Here, it's different.™

INTERNATIONAL CENTER FOR
**COLORECTAL AND
UROGENITAL CARE**



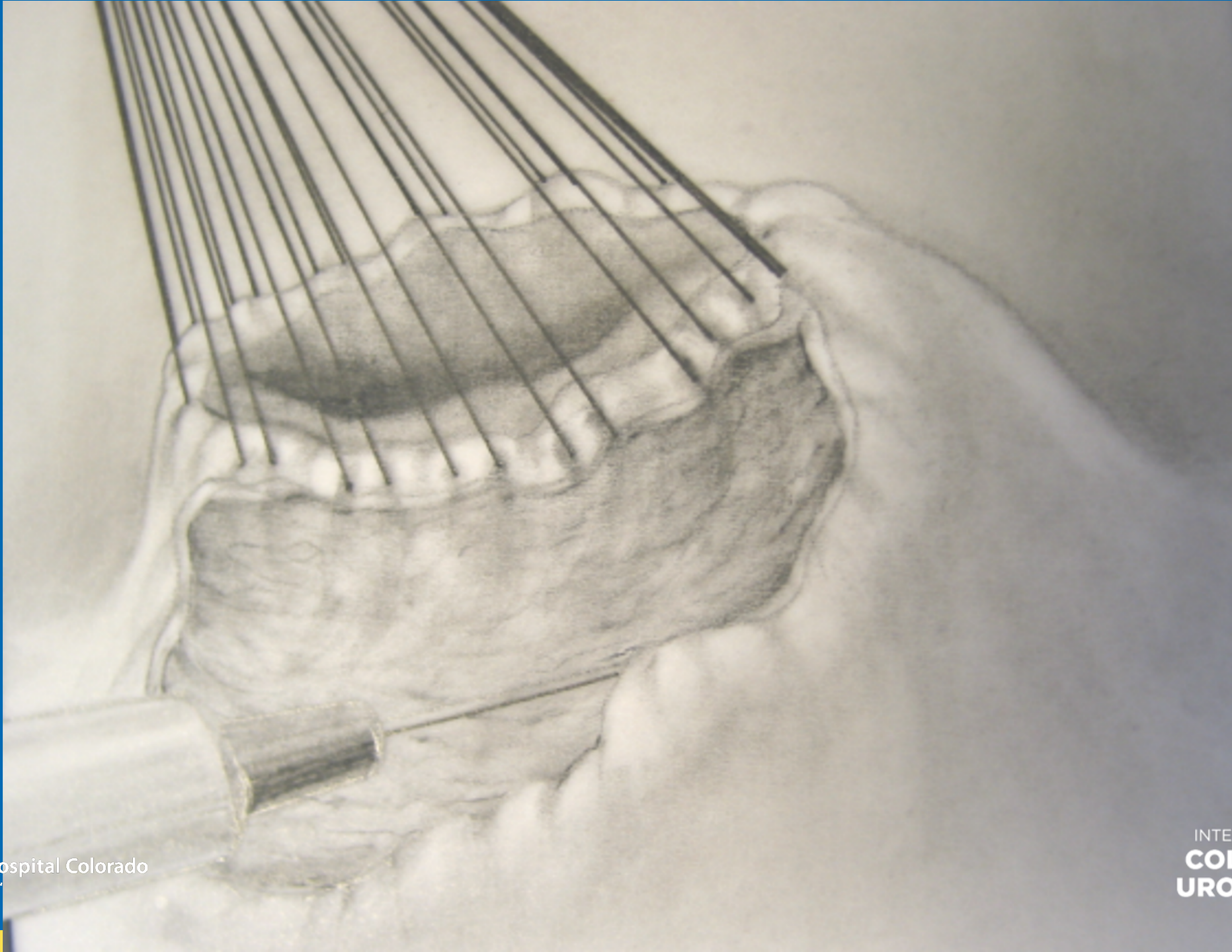
Children's Hospital Colorado
Here, it's different.™

INTERNATIONAL CENTER FOR
**COLORECTAL AND
UROGENITAL CARE**



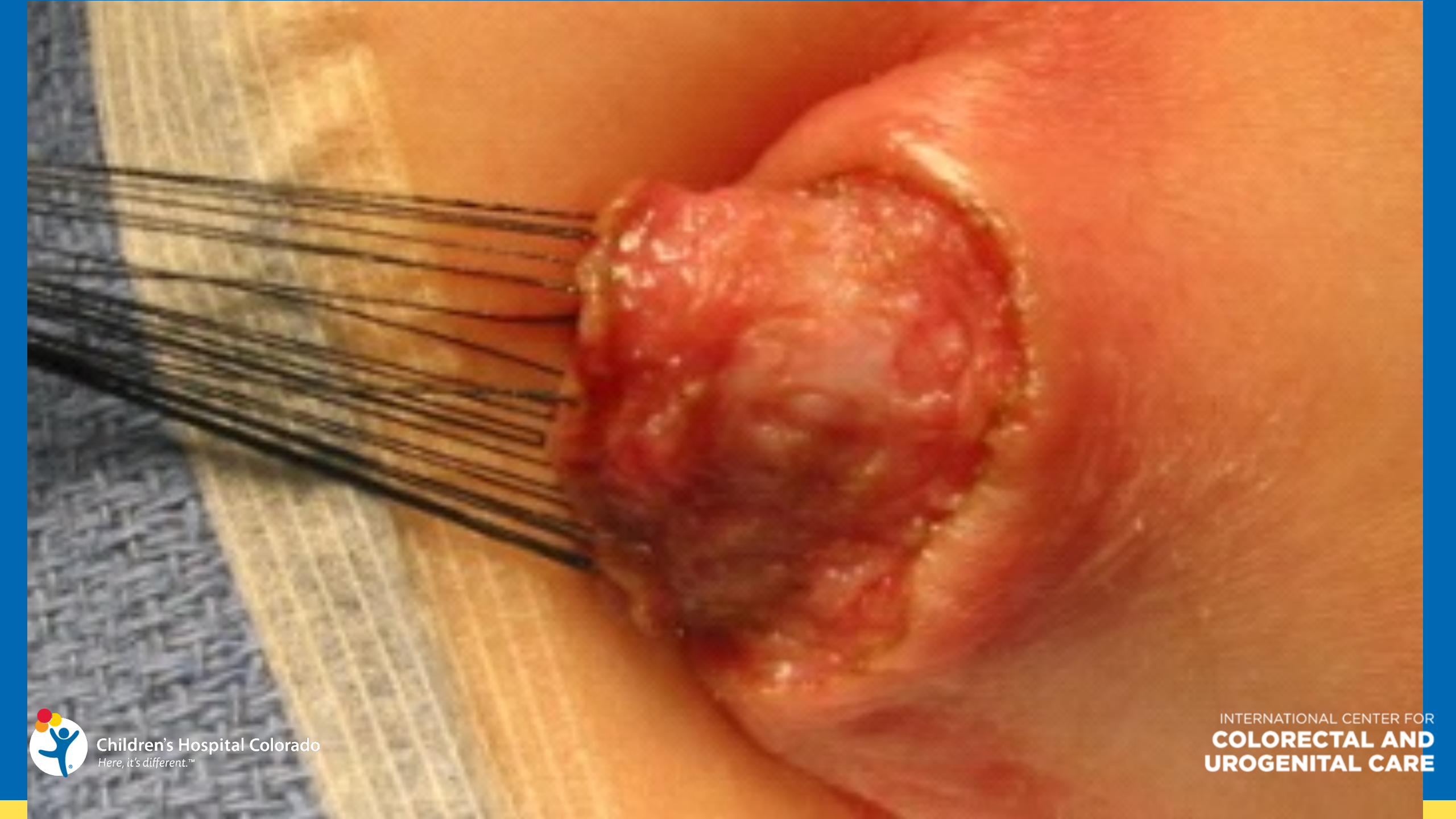Children's Hospital Colorado
Here, it's different.™

INTERNATIONAL CENTER FOR
**COLORECTAL AND
UROGENITAL CARE**



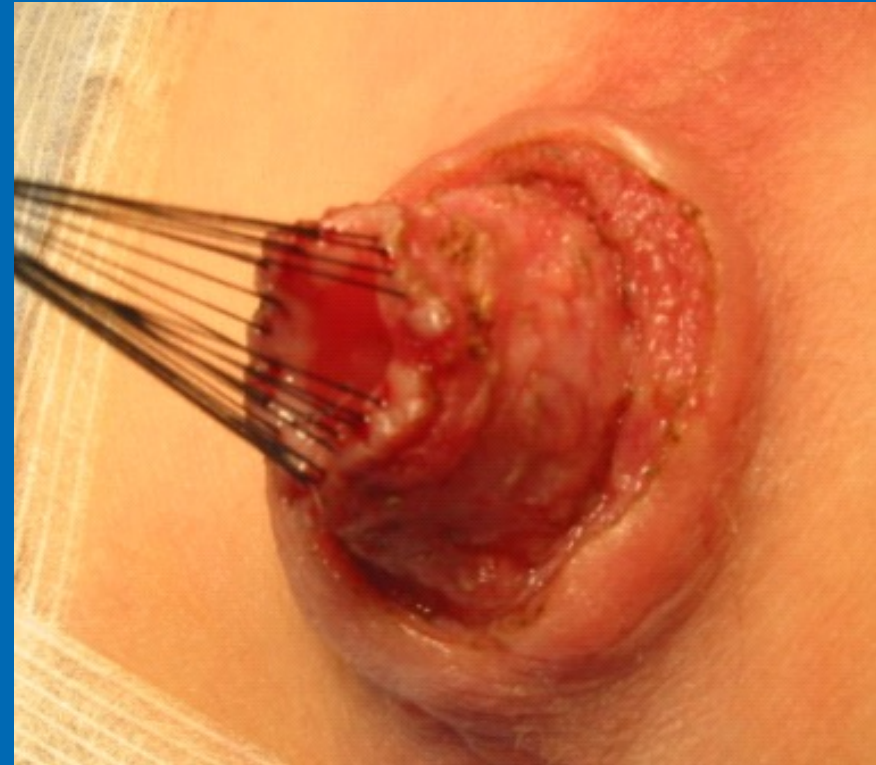
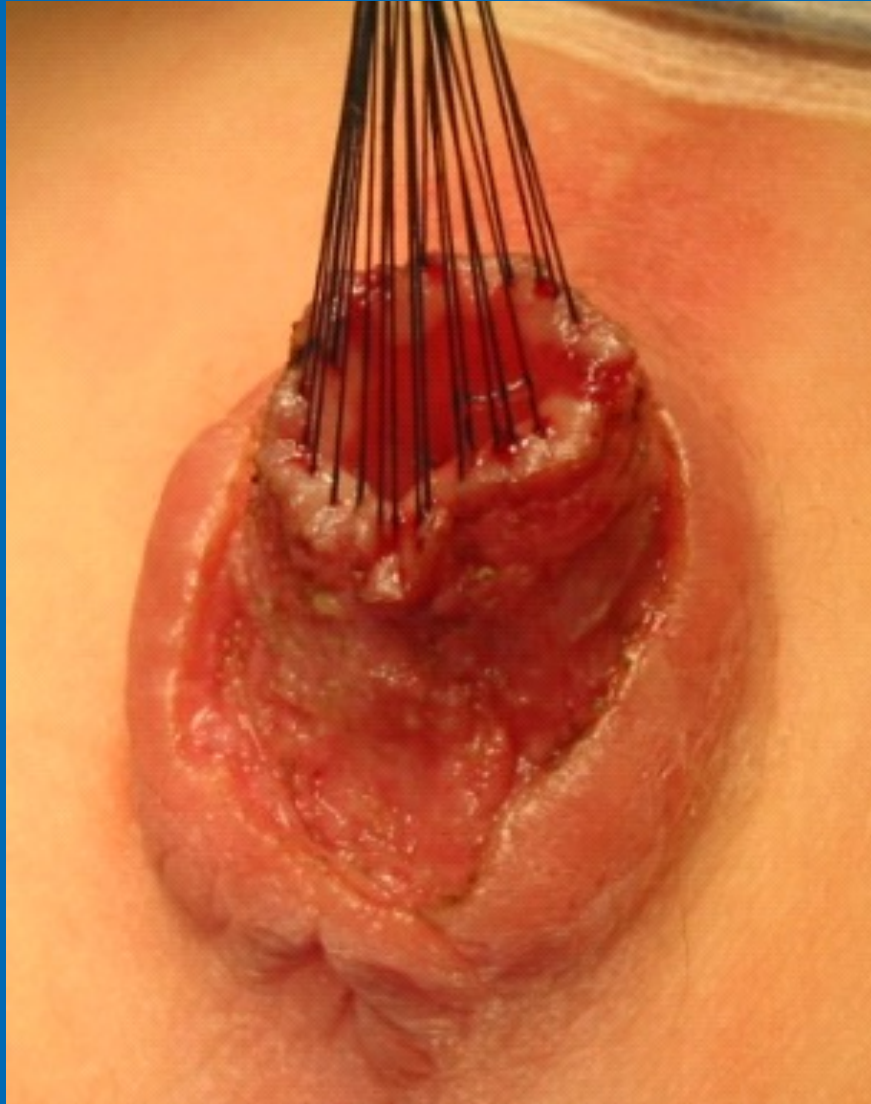
Children's Hospital Colorado
Here, it's different.™

INTERNATIONAL CENTER FOR
**COLORECTAL AND
UROGENITAL CARE**




Children's Hospital Colorado
Here, it's different.™

INTERNATIONAL CENTER FOR
**COLORECTAL AND
UROGENITAL CARE**



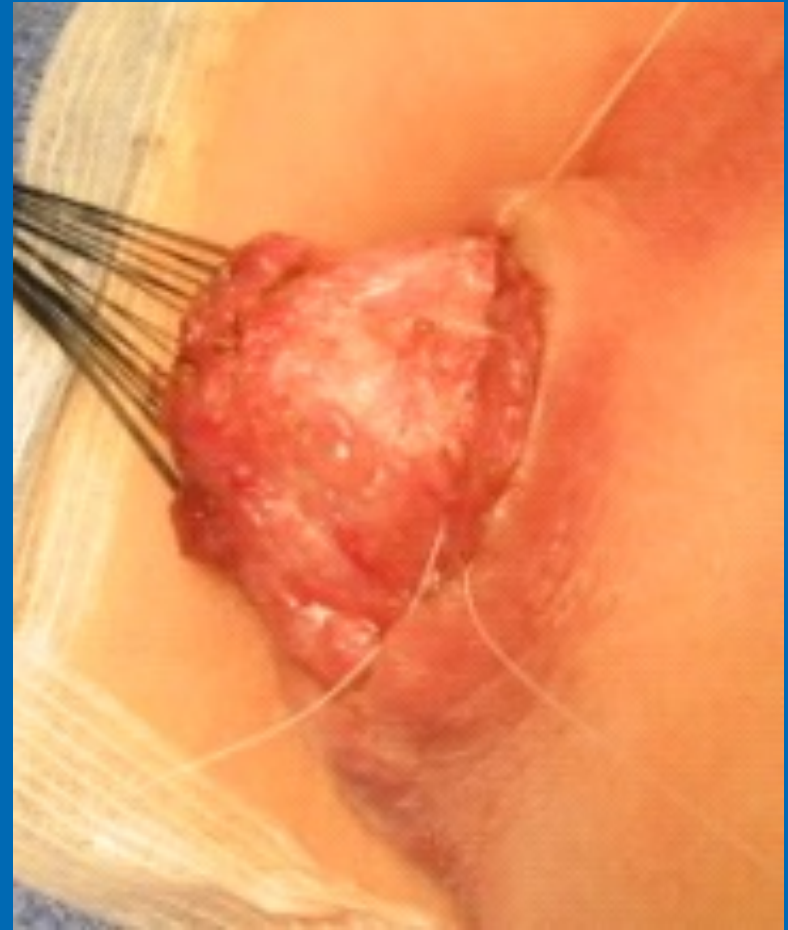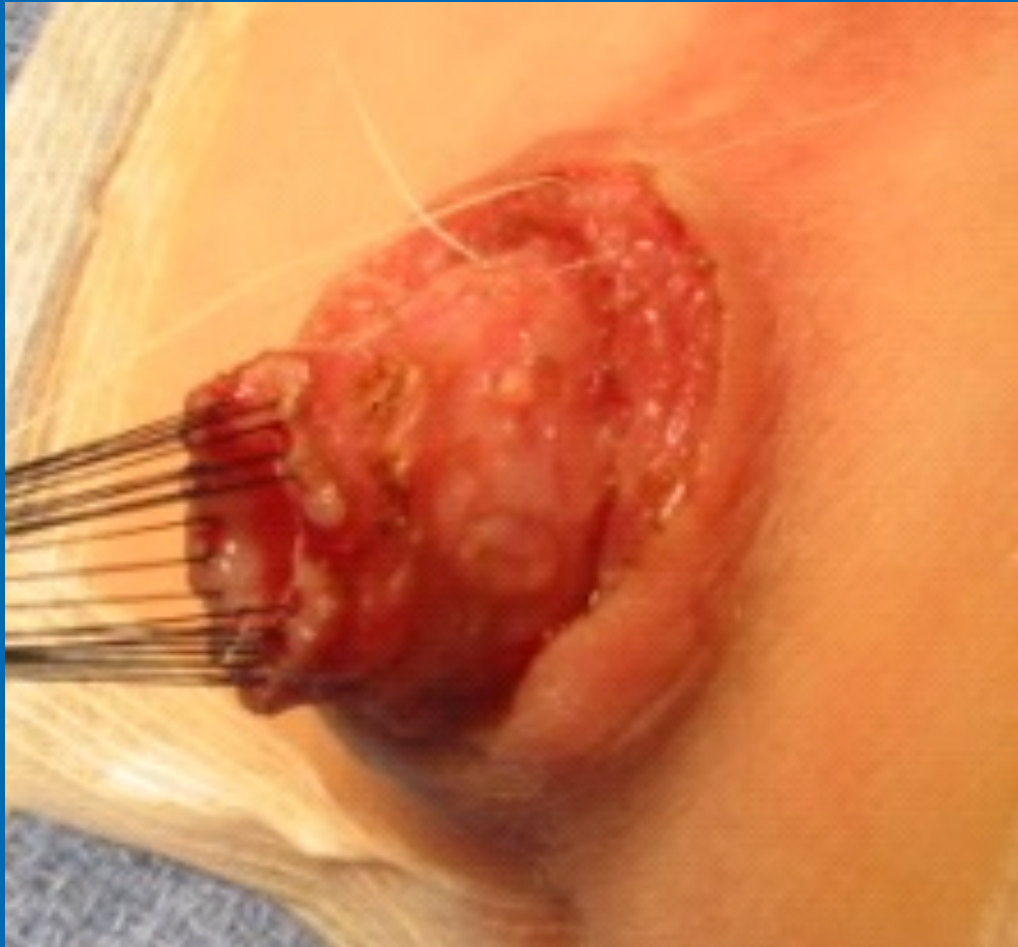Children's Hospital Colorado
Here, it's different.™

INTERNATIONAL CENTER FOR
**COLORECTAL AND
UROGENITAL CARE**



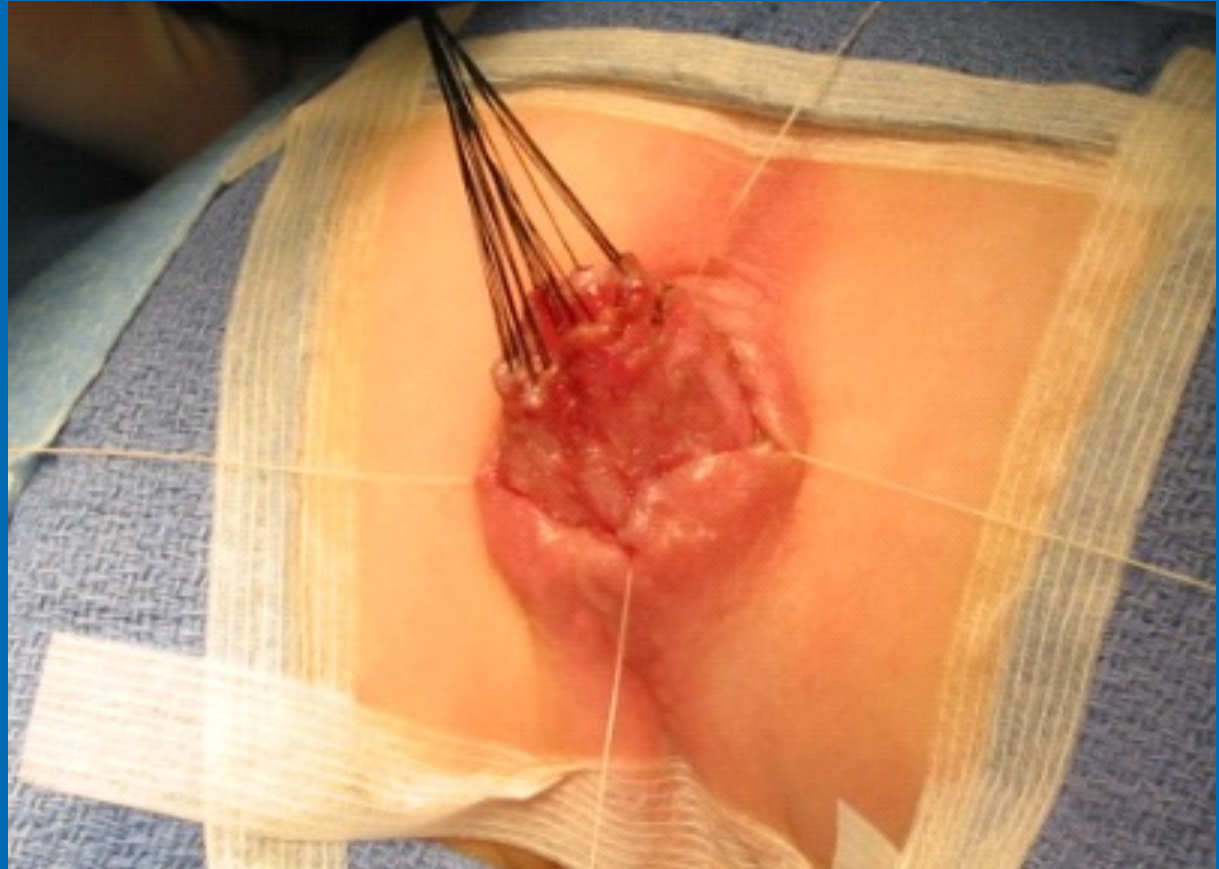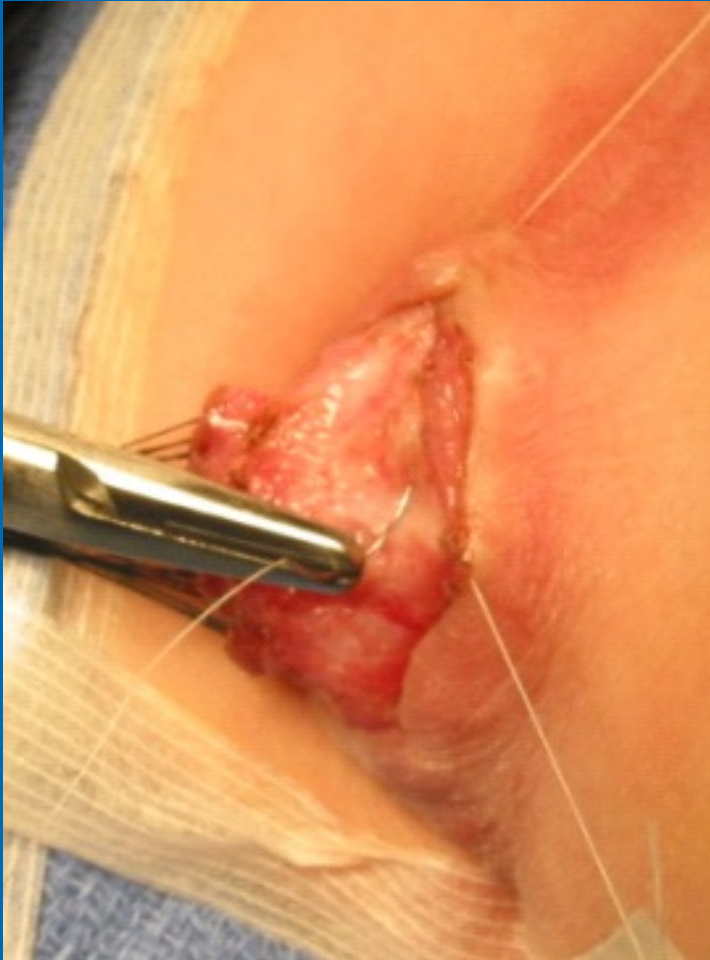
Children's Hospital Colorado
Here, it's different.™

INTERNATIONAL CENTER FOR
**COLORECTAL AND
UROGENITAL CARE**



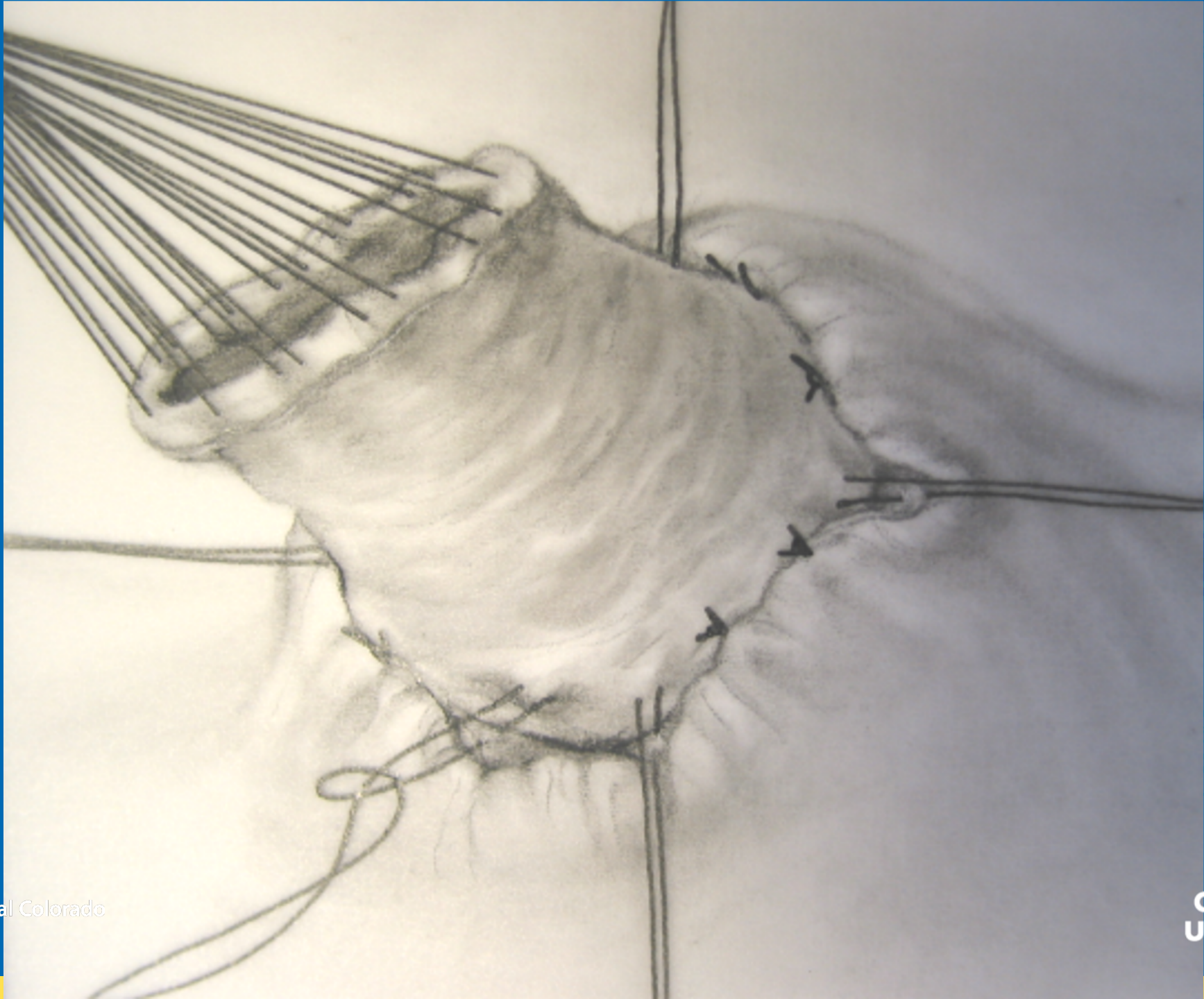
Children's Hospital Colorado
Here, it's different.™

INTERNATIONAL CENTER FOR
**COLORECTAL AND
UROGENITAL CARE**



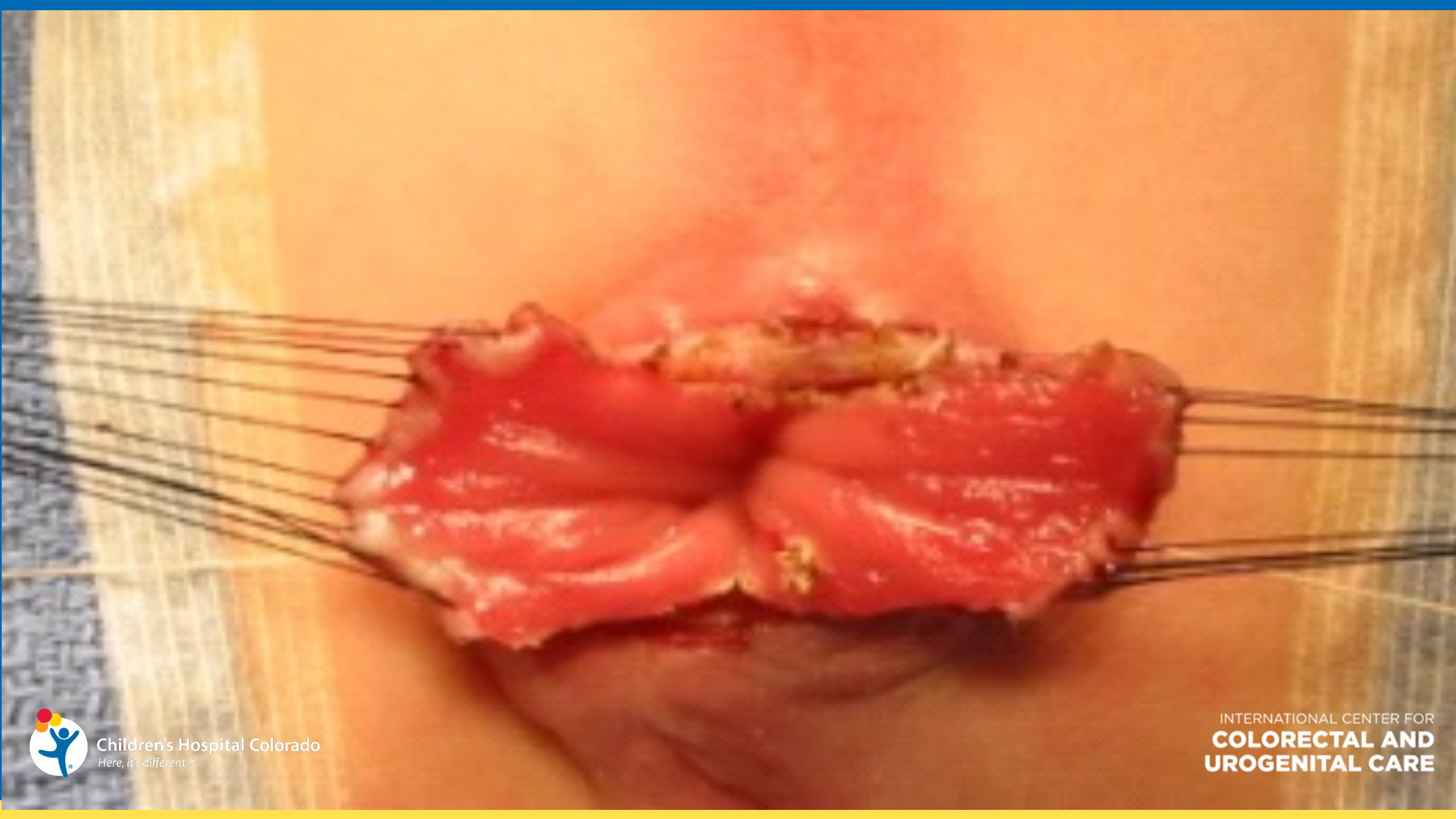
Children's Hospital Colorado
Here, it's different.™

INTERNATIONAL CENTER FOR
**COLORECTAL AND
UROGENITAL CARE**



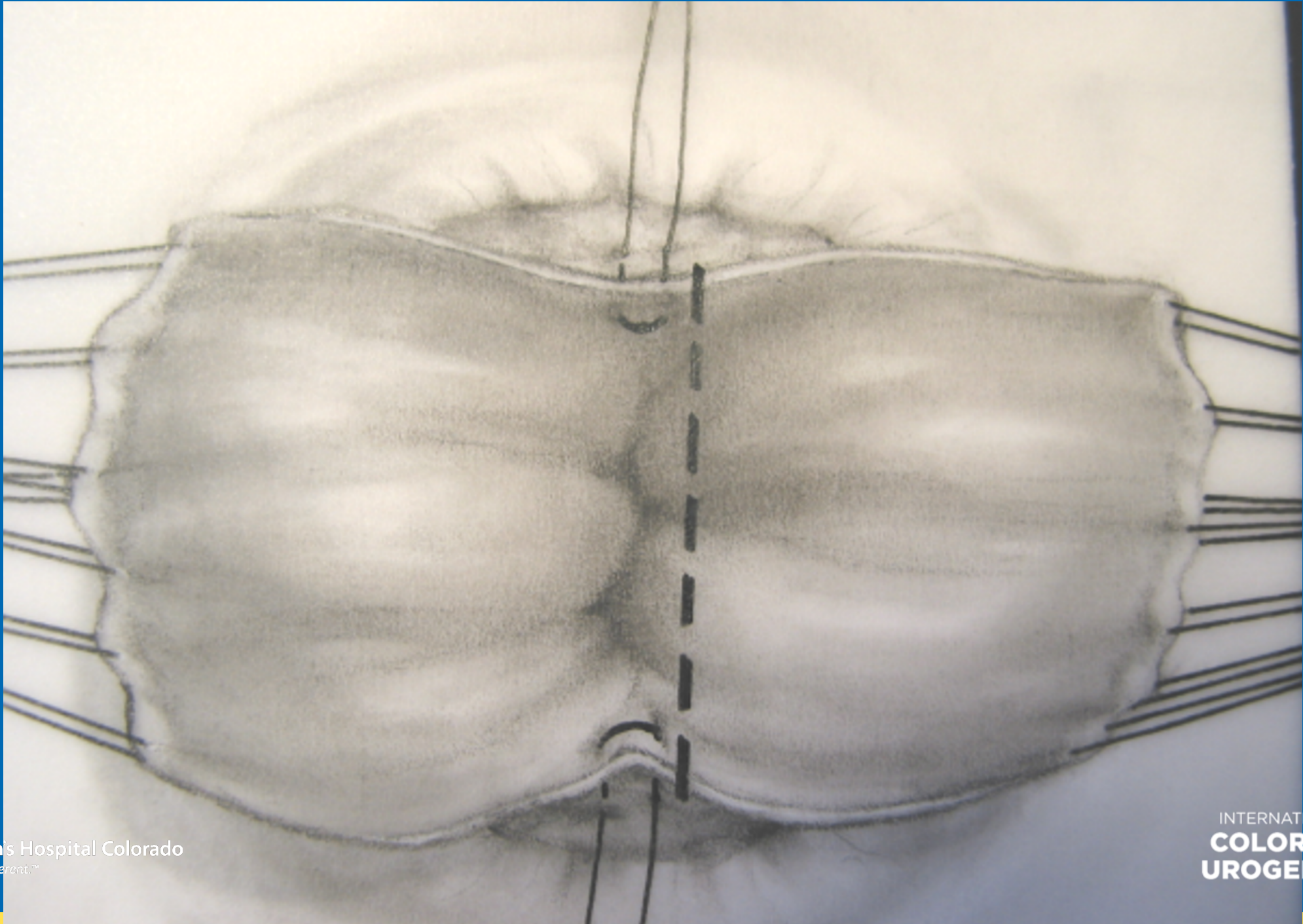
Children's Hospital Colorado
Here, it's different.™

INTERNATIONAL CENTER FOR
**COLORECTAL AND
UROGENITAL CARE**



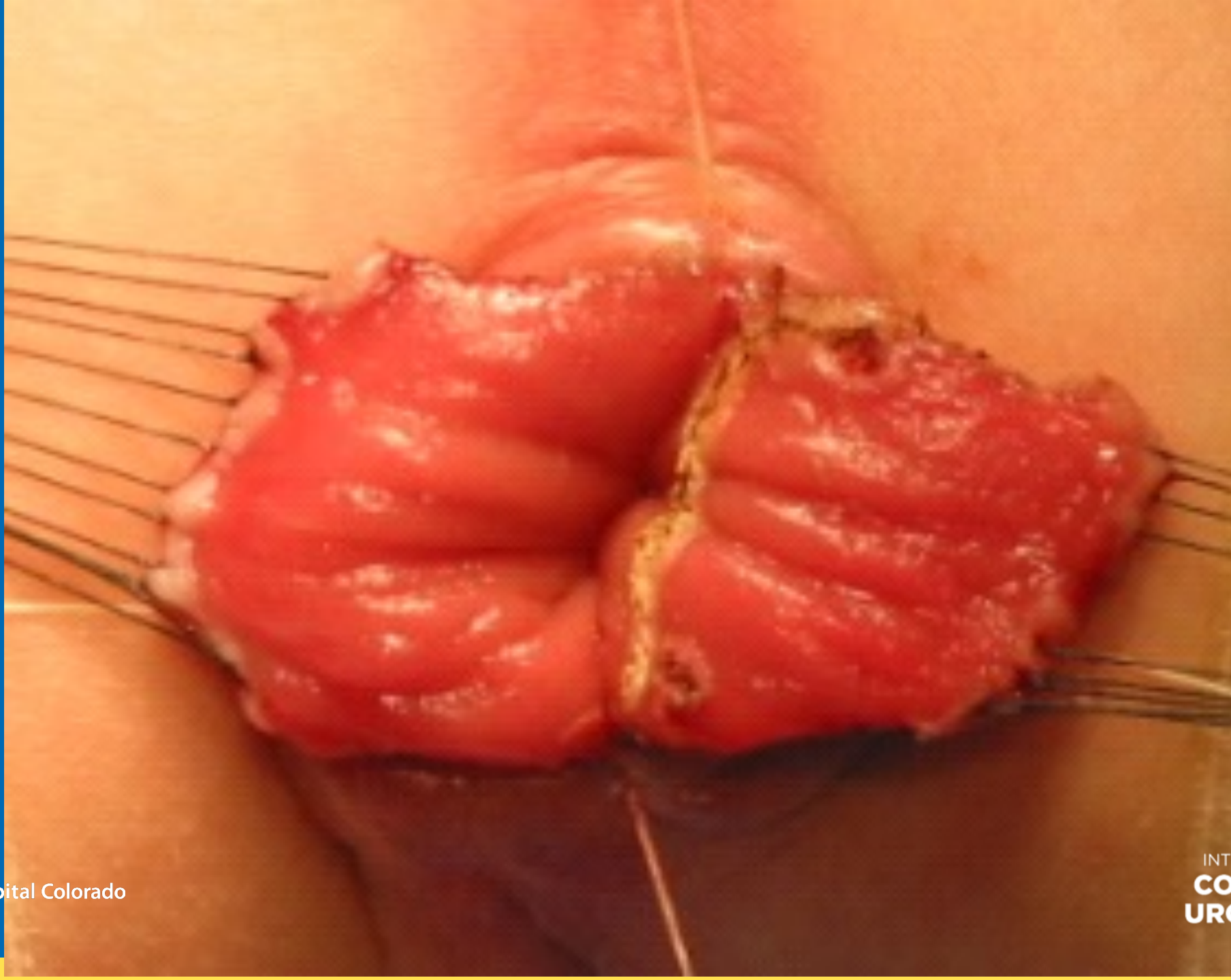
Children's Hospital Colorado
Here, it's different.™

INTERNATIONAL CENTER FOR
**COLORECTAL AND
UROGENITAL CARE**



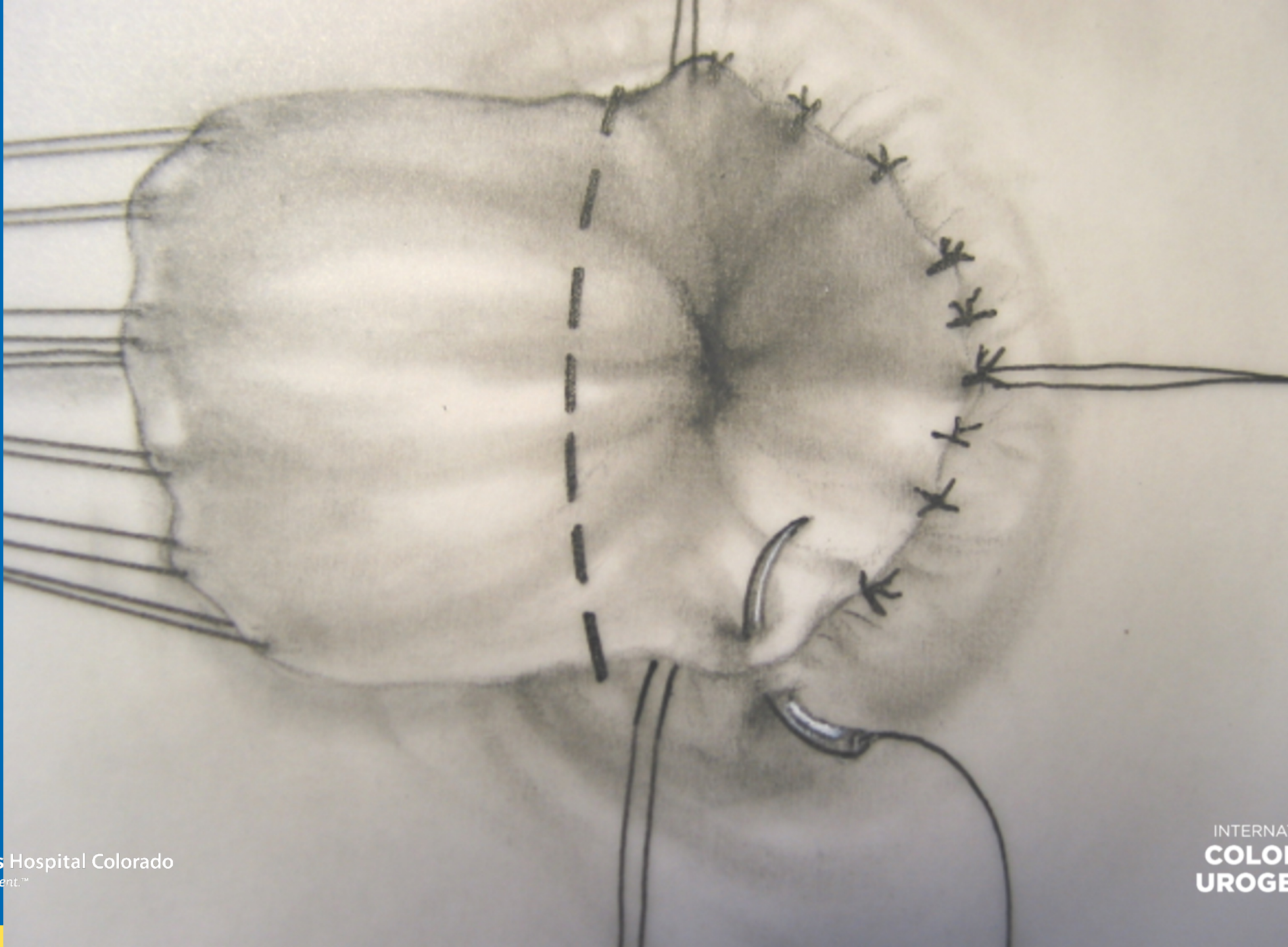
Children's Hospital Colorado
Here, it's different.™

INTERNATIONAL CENTER FOR
**COLORECTAL AND
UROGENITAL CARE**



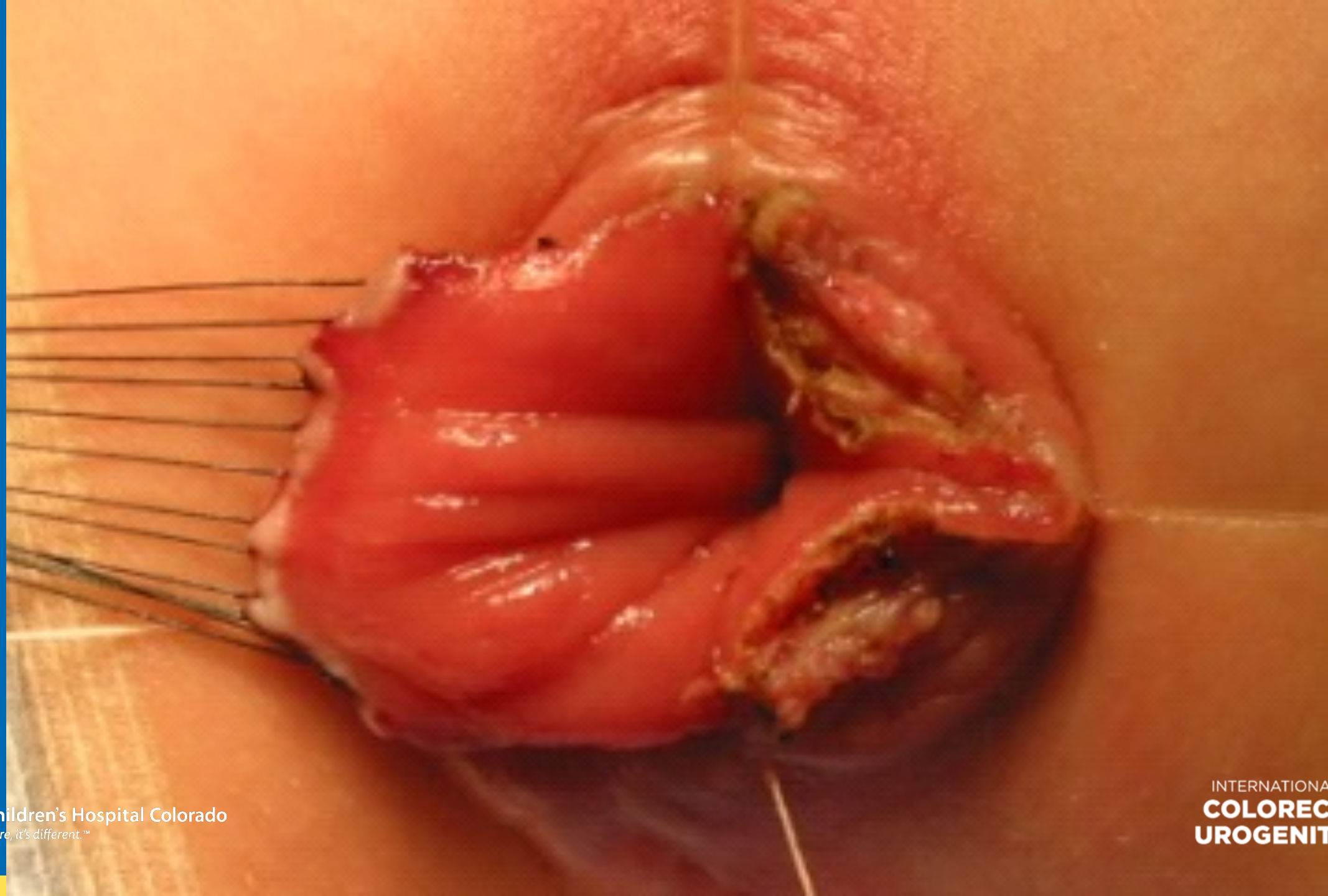
Children's Hospital Colorado
Here, it's different.™

INTERNATIONAL CENTER FOR
**COLORECTAL AND
UROGENITAL CARE**



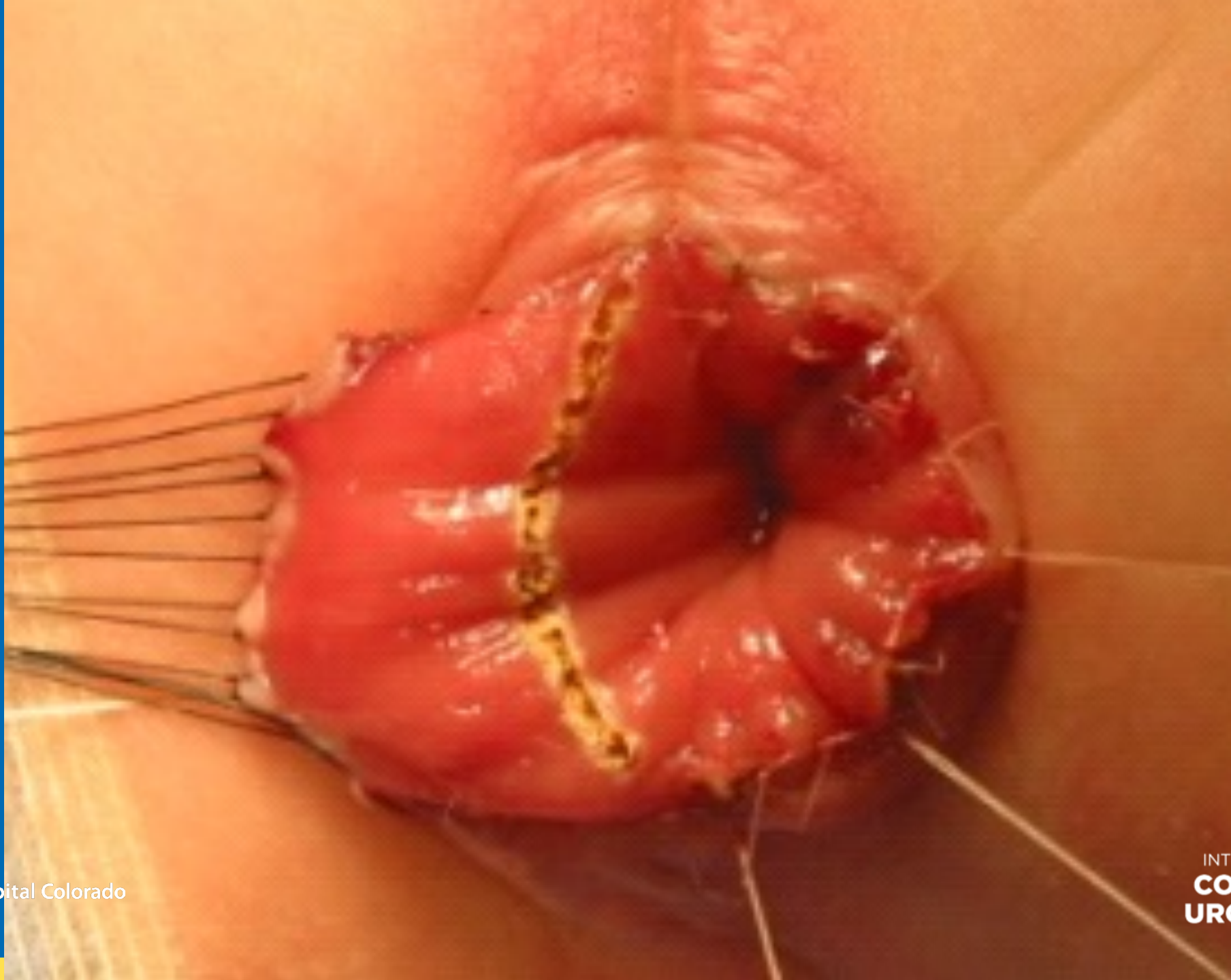
Children's Hospital Colorado
Here, it's different.™

INTERNATIONAL CENTER FOR
**COLORECTAL AND
UROGENITAL CARE**



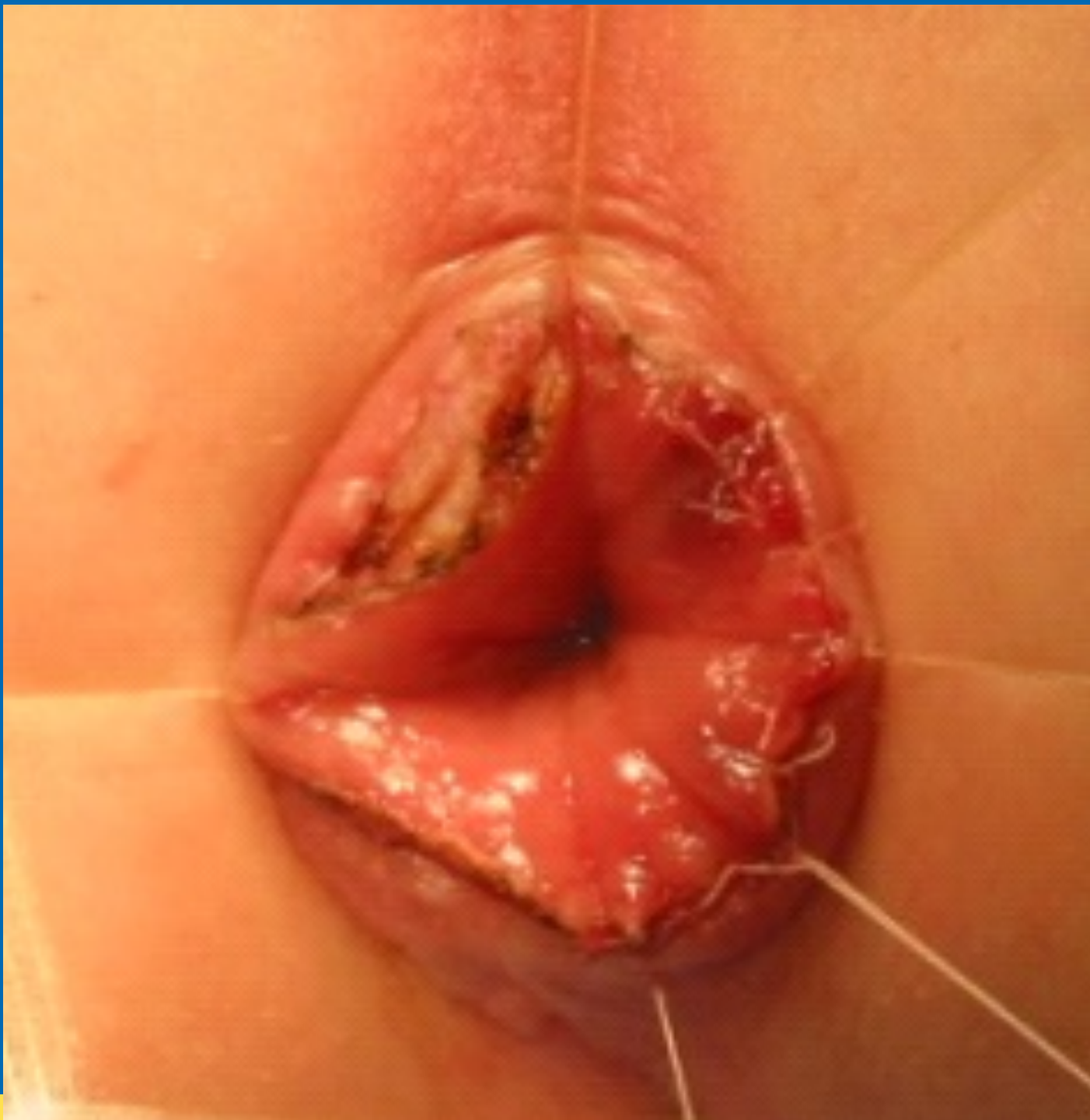Children's Hospital Colorado
Here, it's different.™

INTERNATIONAL CENTER FOR
**COLORECTAL AND
UROGENITAL CARE**



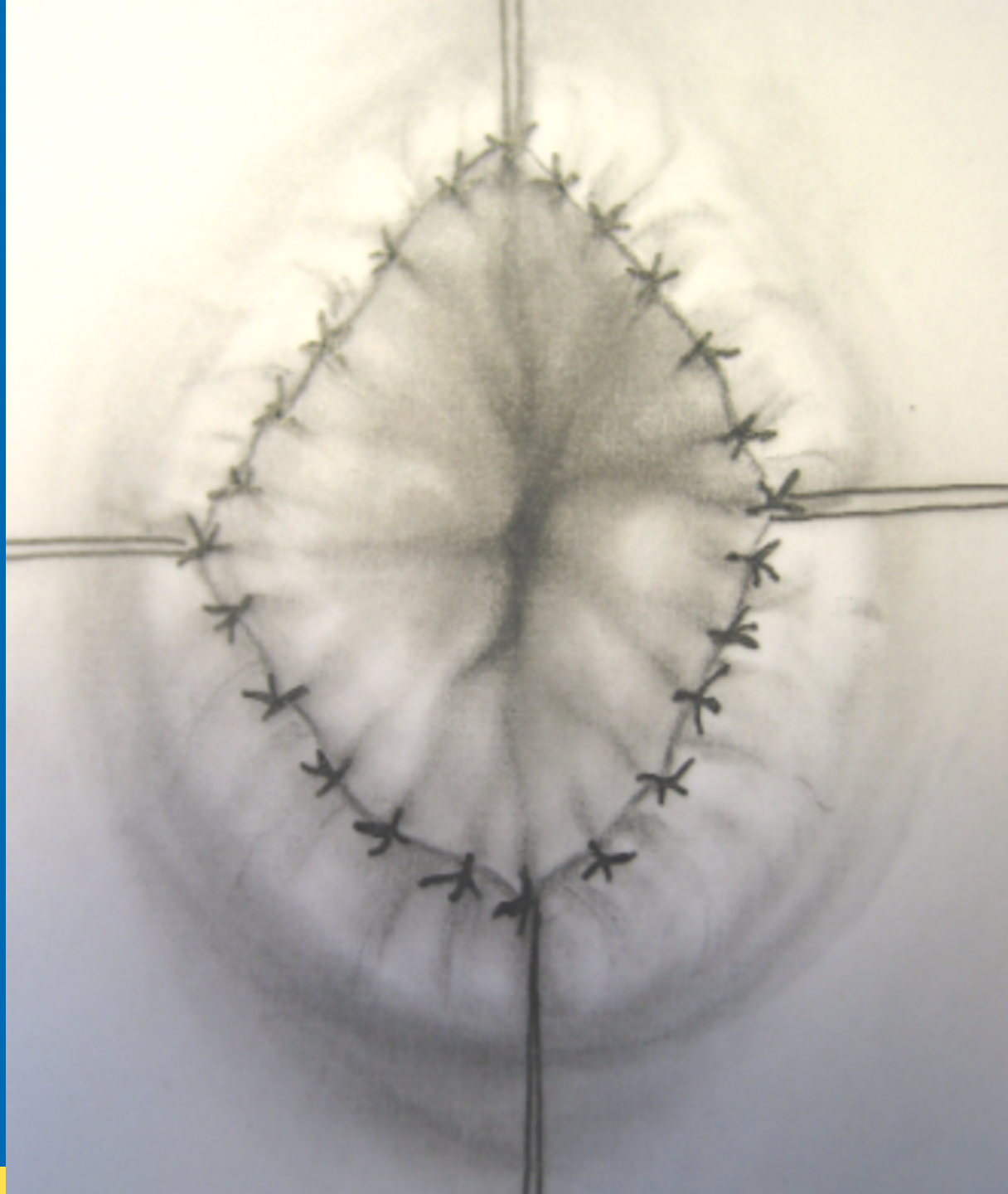
Children's Hospital Colorado
Here, it's different.™

INTERNATIONAL CENTER FOR
**COLORECTAL AND
UROGENITAL CARE**



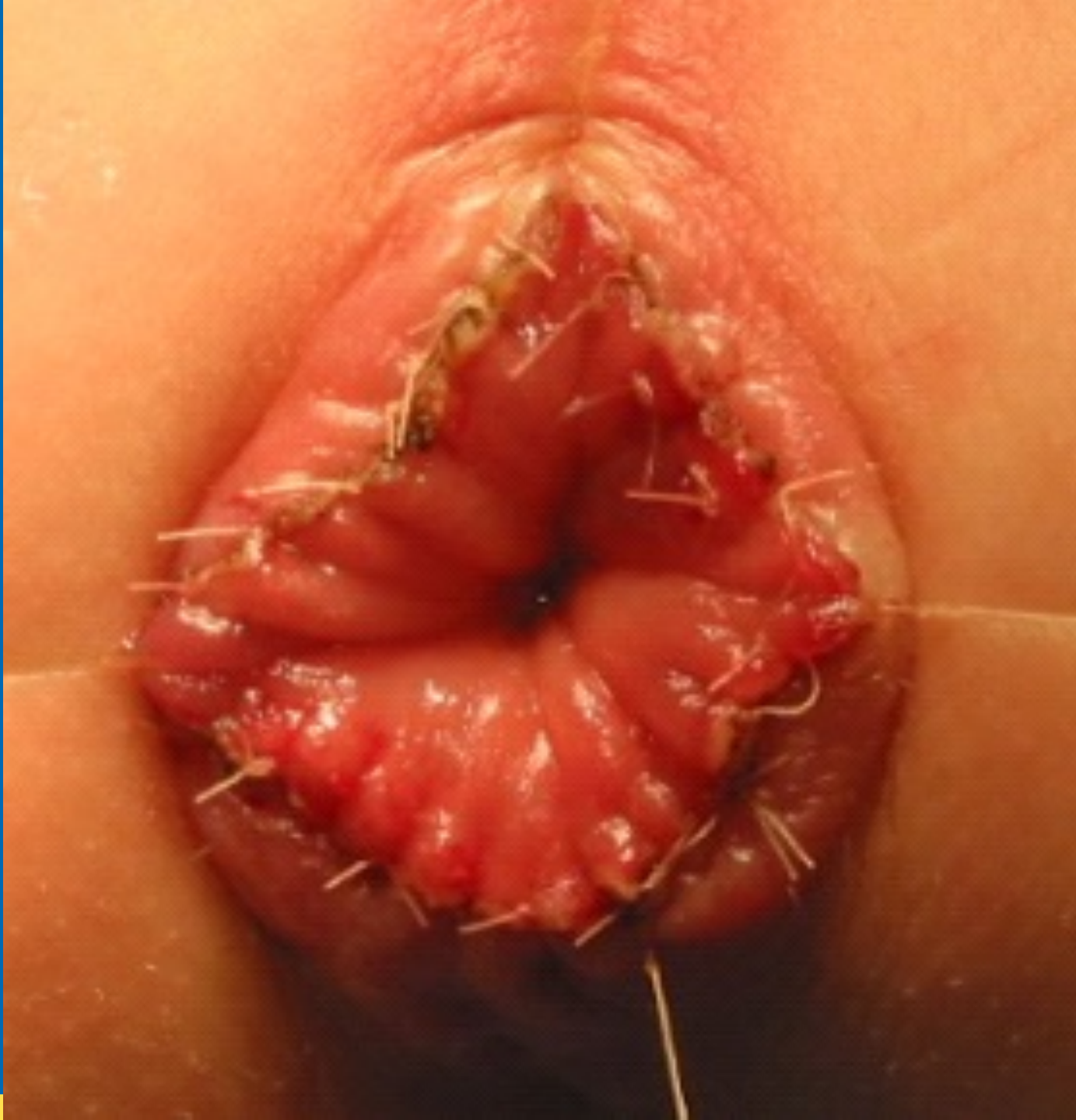Children's Hospital Colorado
Here, it's different.™

INTERNATIONAL CENTER FOR
**COLORECTAL AND
UROGENITAL CARE**



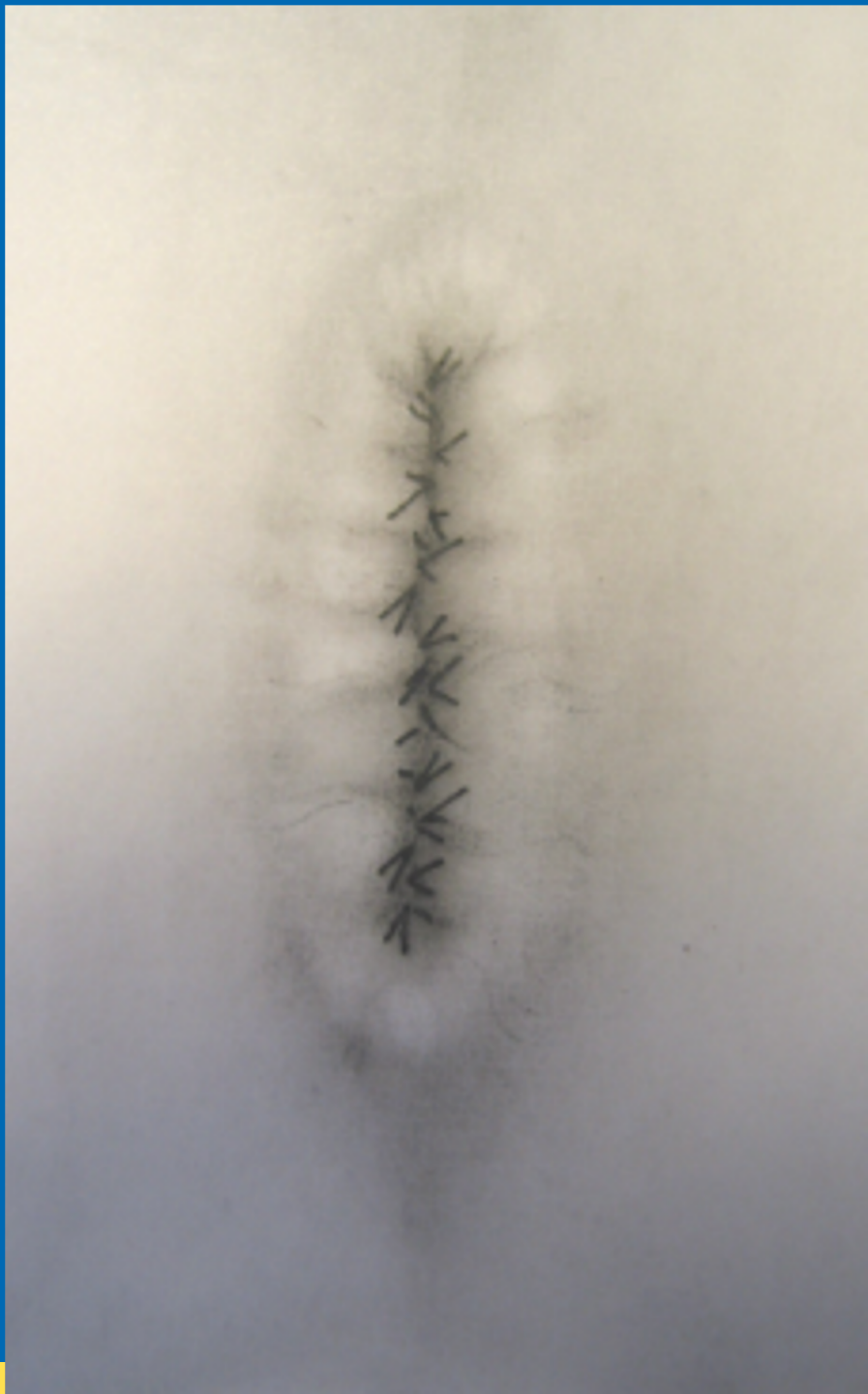Children's Hospital Colorado
Here, it's different.™

INTERNATIONAL CENTER FOR
**COLORECTAL AND
UROGENITAL CARE**



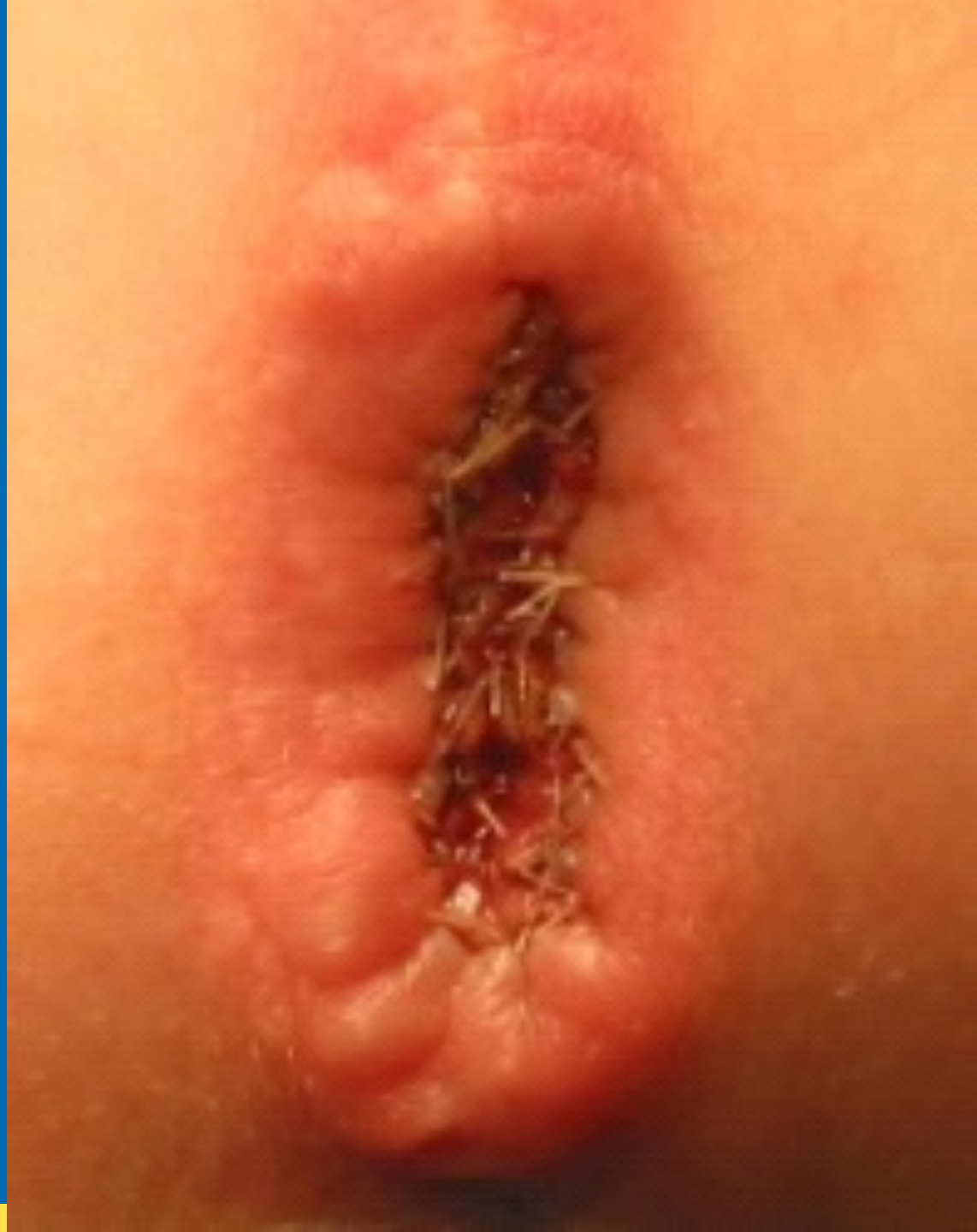Children's Hospital Colorado
Here, it's different.™

INTERNATIONAL CENTER FOR
**COLORECTAL AND
UROGENITAL CARE**



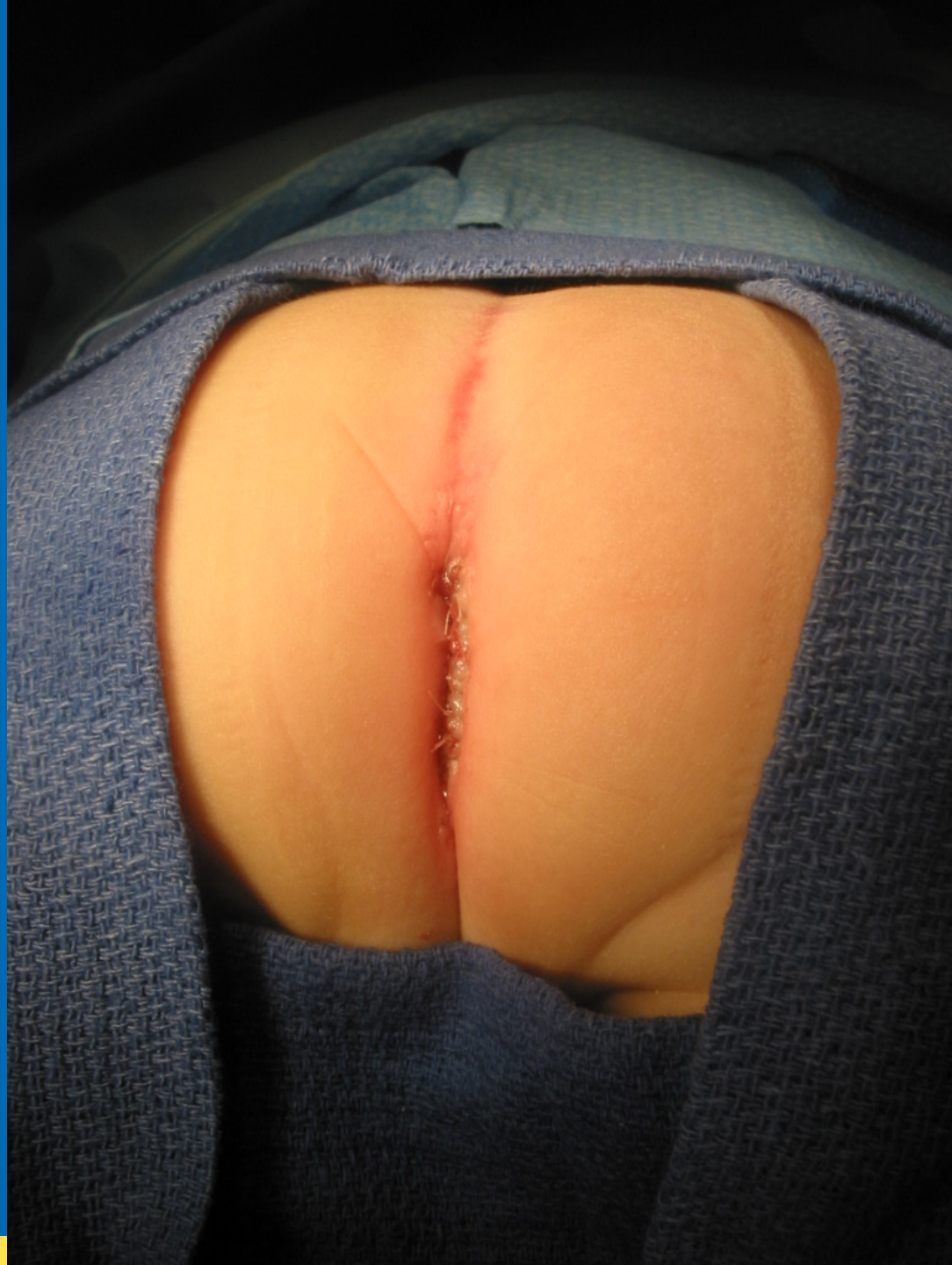Children's Hospital Colorado
Here, it's different.™

INTERNATIONAL CENTER FOR
**COLORECTAL AND
UROGENITAL CARE**



Children's Hospital Colorado
Here, it's different.™

INTERNATIONAL CENTER FOR
**COLORECTAL AND
UROGENITAL CARE**



Children's Hospital Colorado
Here, it's different.™

INTERNATIONAL CENTER FOR
**COLORECTAL AND
UROGENITAL CARE**

Rectal prolapse after PSARP

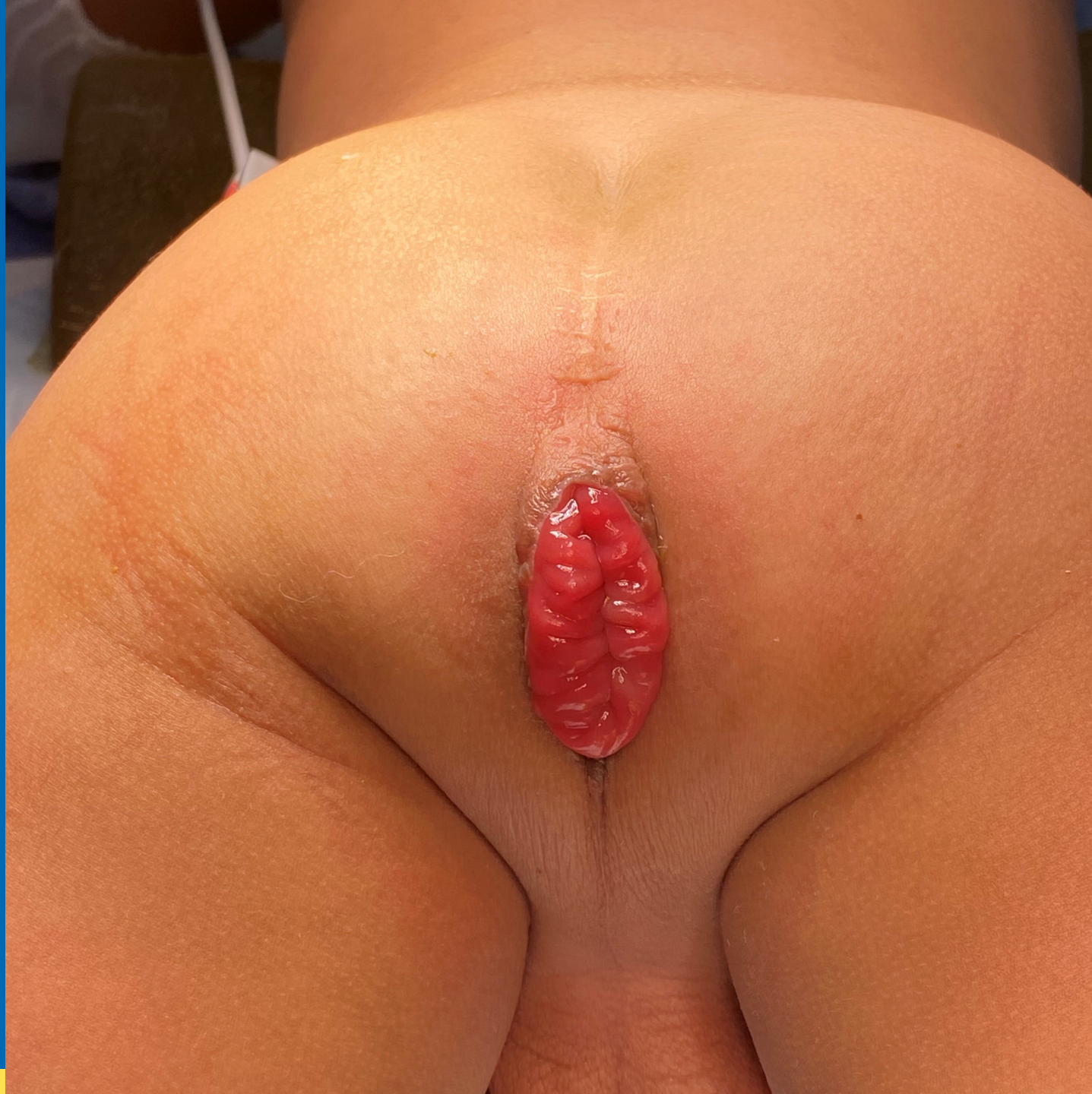Transanal rectal mucosectomy and muscular plication

Luis de la Torre, MD

The 65th Workshop for the Surgical Treatment
of Colorectal Problems in Children

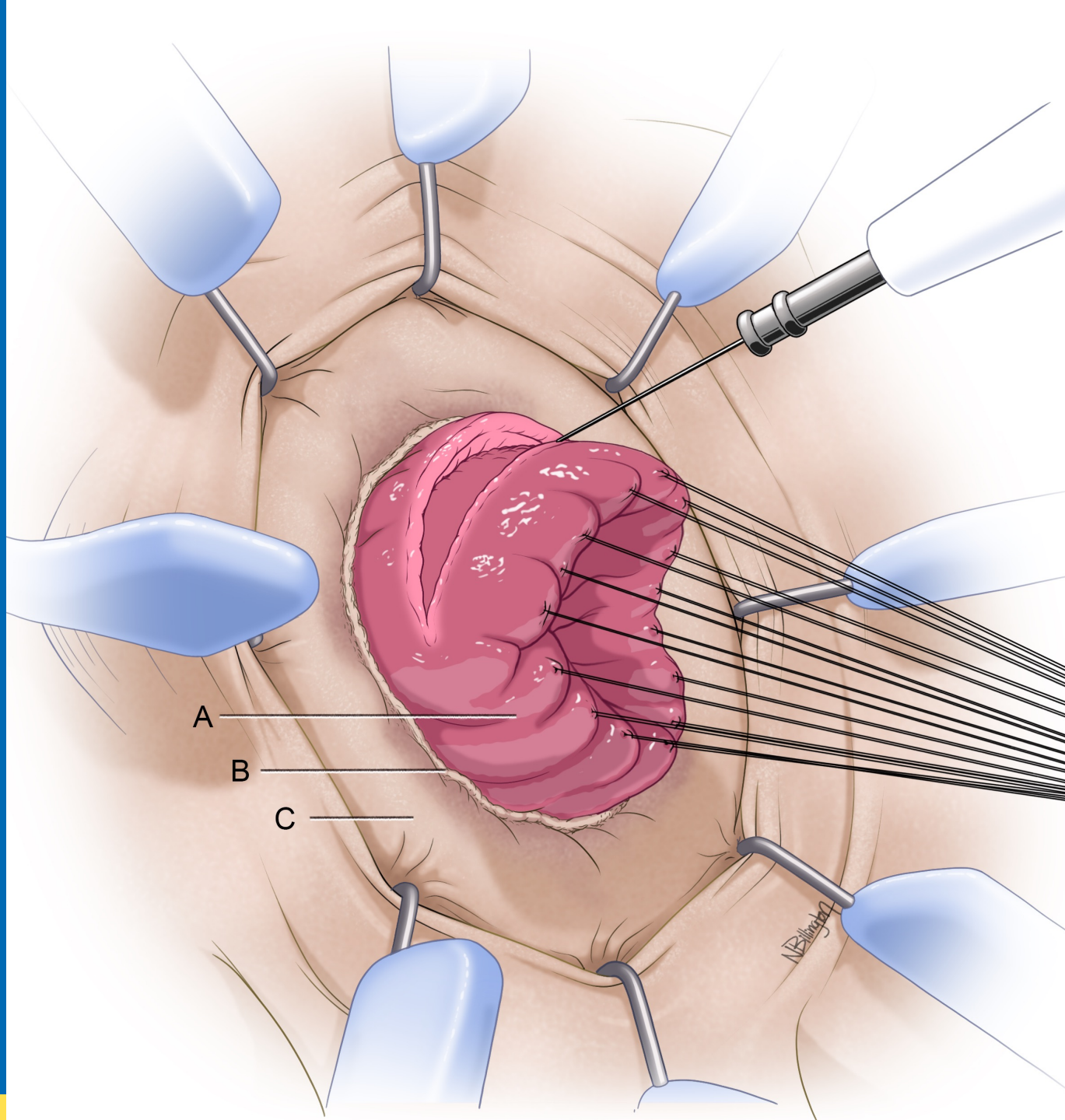


Children's Hospital Colorado
Here, it's different.™



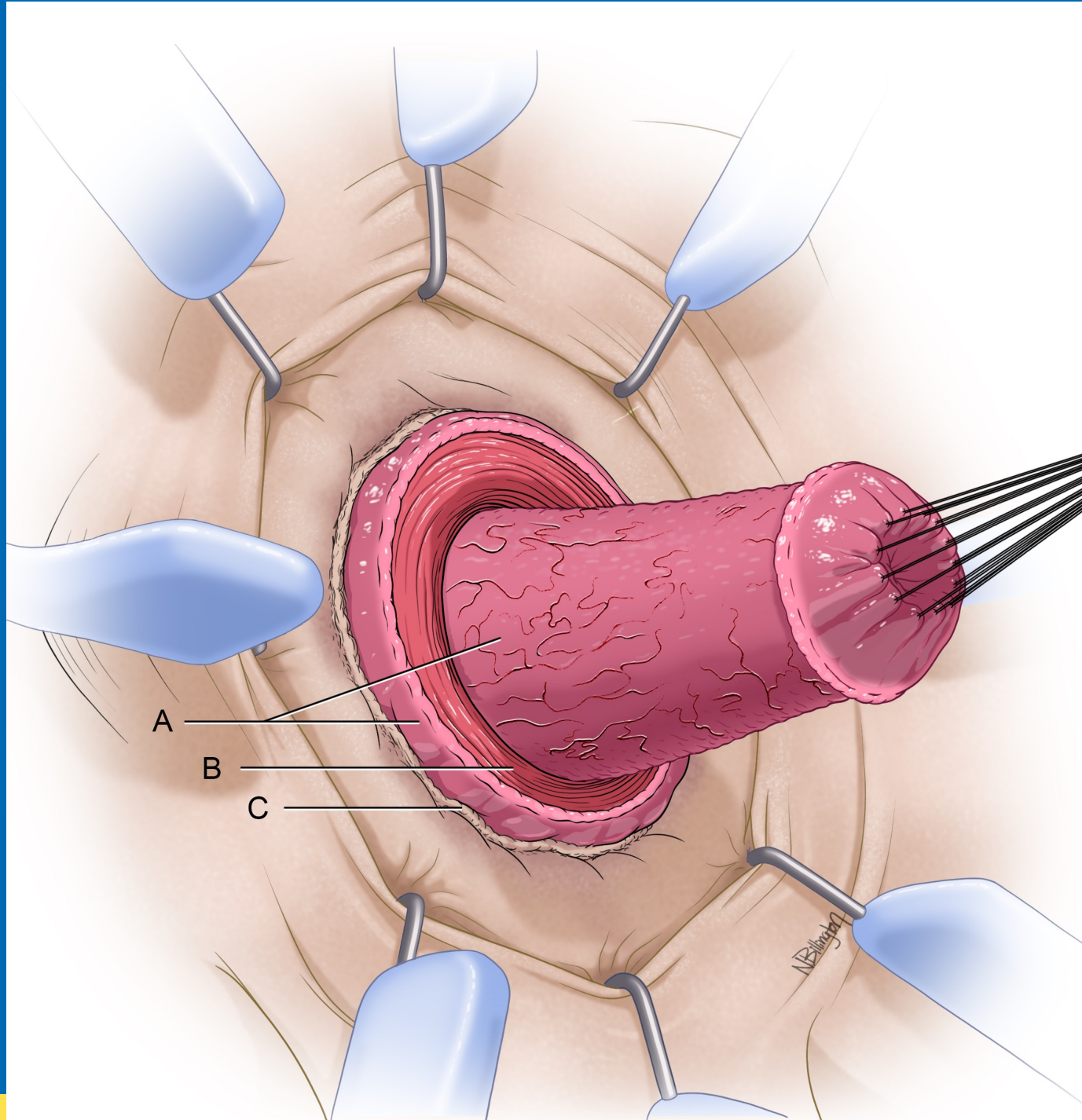
Children's Hospital Colorado
Here, it's different.™

INTERNATIONAL CENTER FOR
**COLORECTAL AND
UROGENITAL CARE**



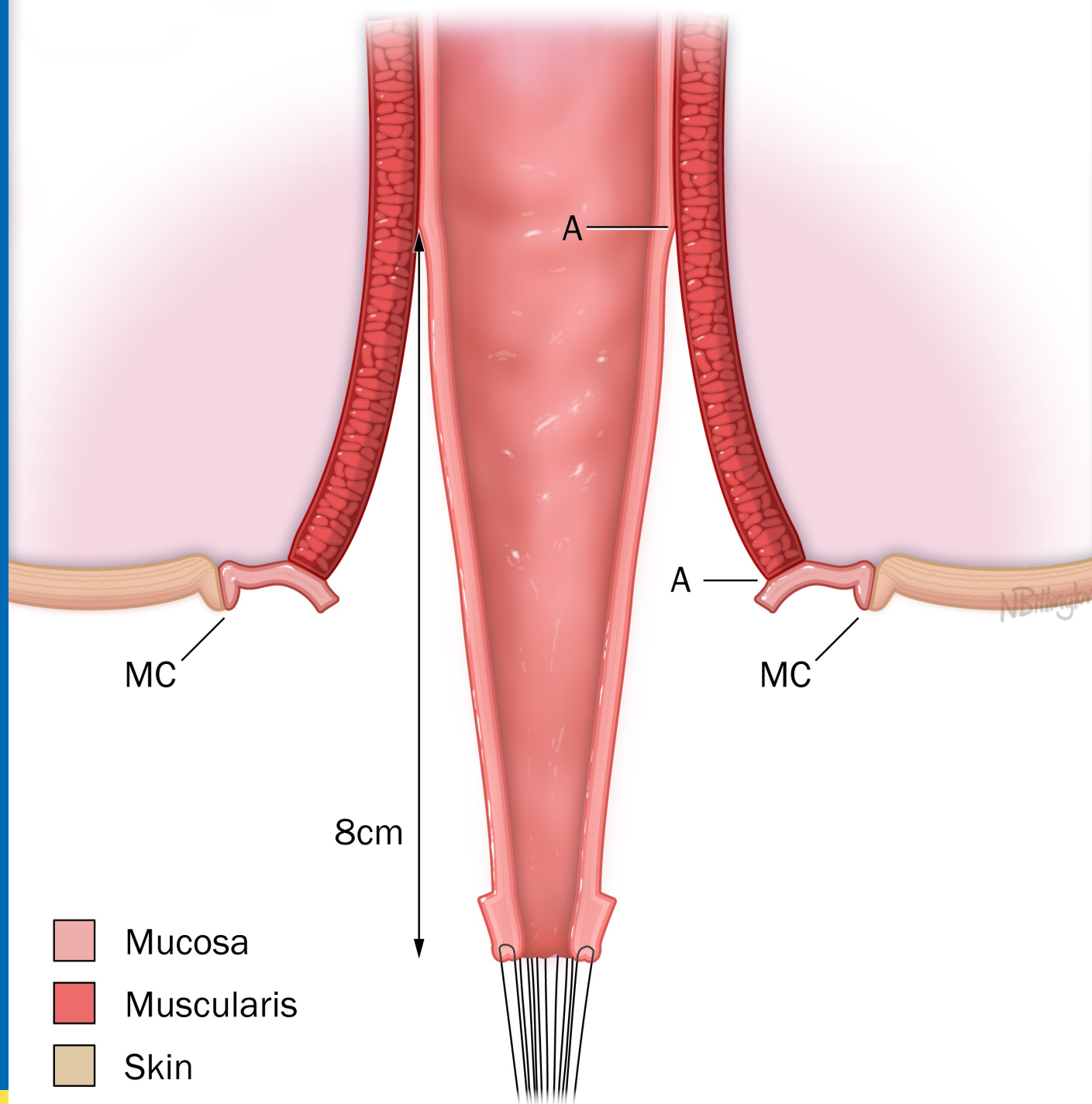
Children's Hospital Colorado
Here, it's different.™




INTERNATIONAL CENTER FOR
**COLORECTAL AND
UROGENITAL CARE**



Children's Hospital Colorado
Here, it's different.™

INTERNATIONAL CENTER FOR
**COLORECTAL AND
UROGENITAL CARE**

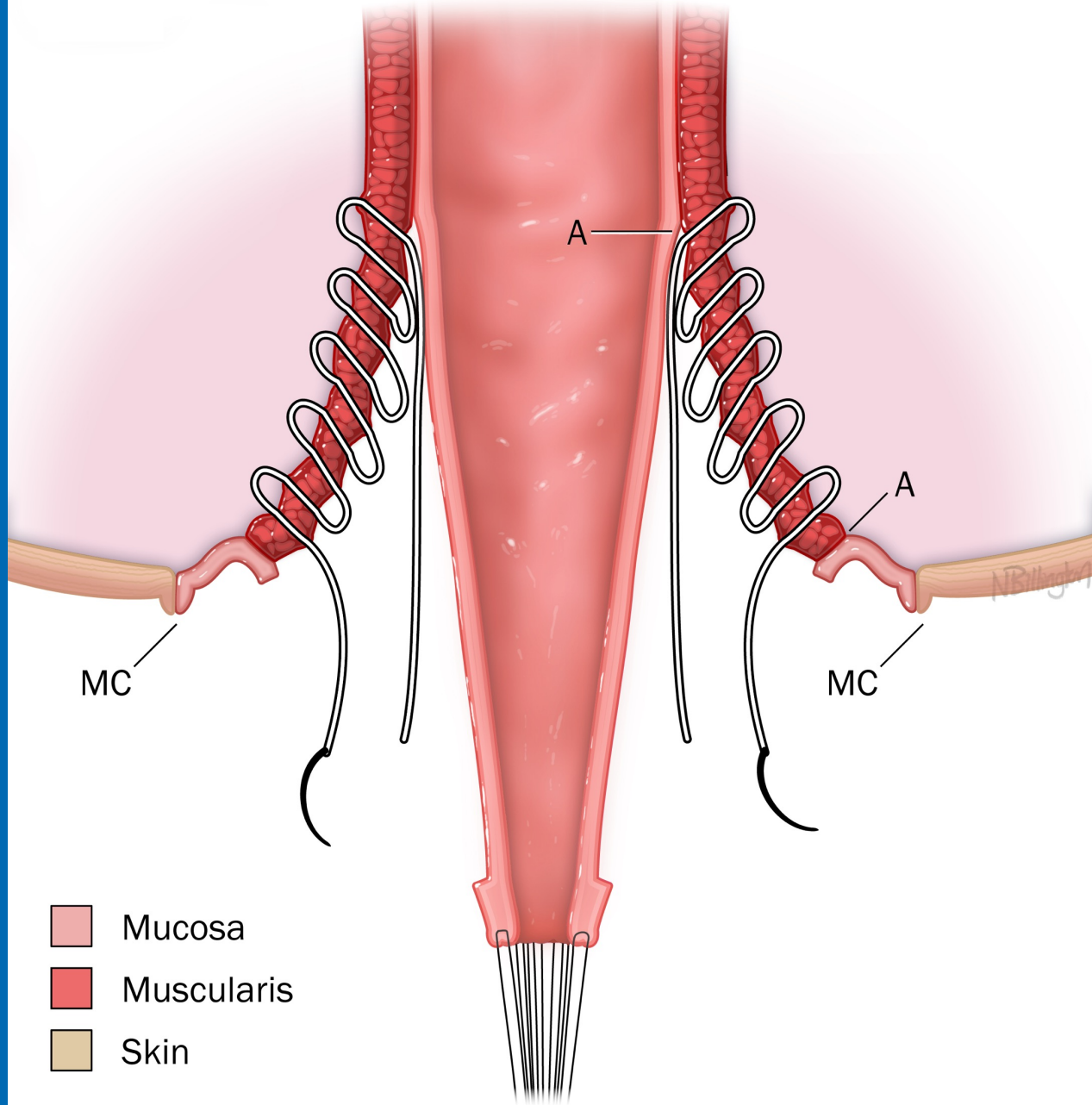


-  Mucosa
-  Muscularis
-  Skin



Children's Hospital Colorado
Here, it's different.™

INTERNATIONAL CENTER FOR
**COLORECTAL AND
UROGENITAL CARE**

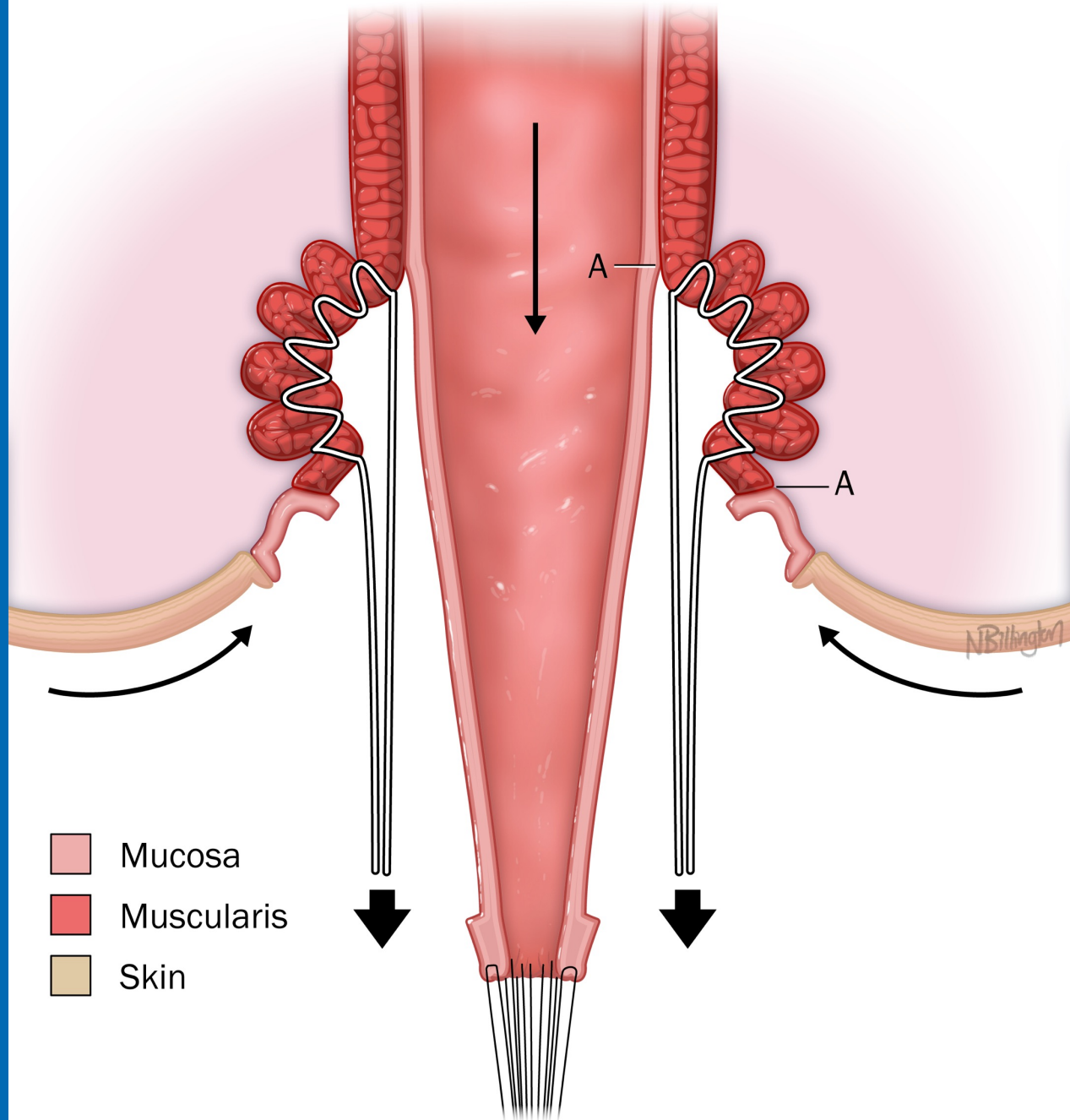


- Mucosa
- Muscularis
- Skin



Children's Hospital Colorado
Here, it's different.™

INTERNATIONAL CENTER FOR
**COLORECTAL AND
UROGENITAL CARE**

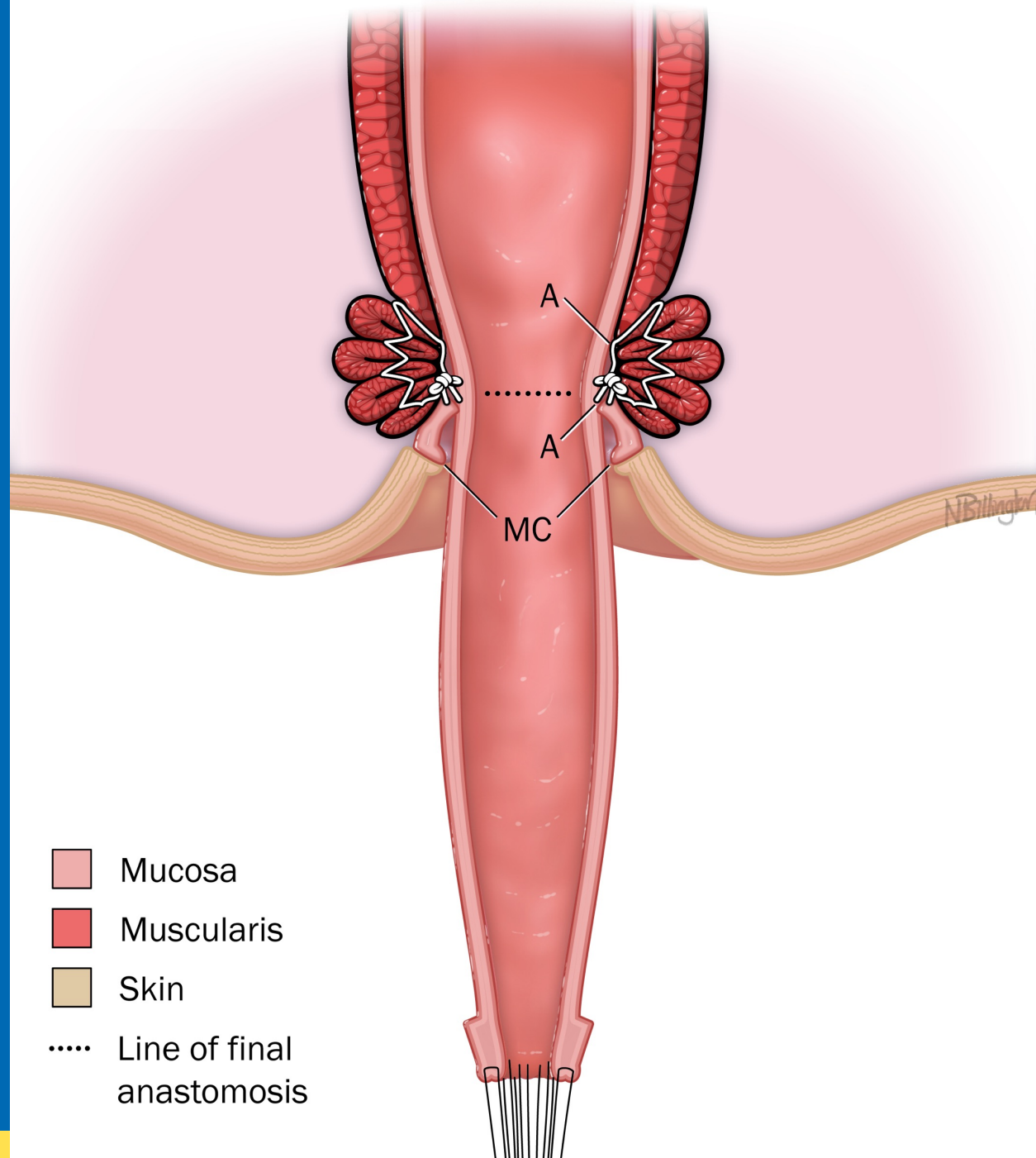






- Mucosa
- Muscularis
- Skin



Children's Hospital Colorado
Here, it's different.™

INTERNATIONAL CENTER FOR
**COLORECTAL AND
UROGENITAL CARE**

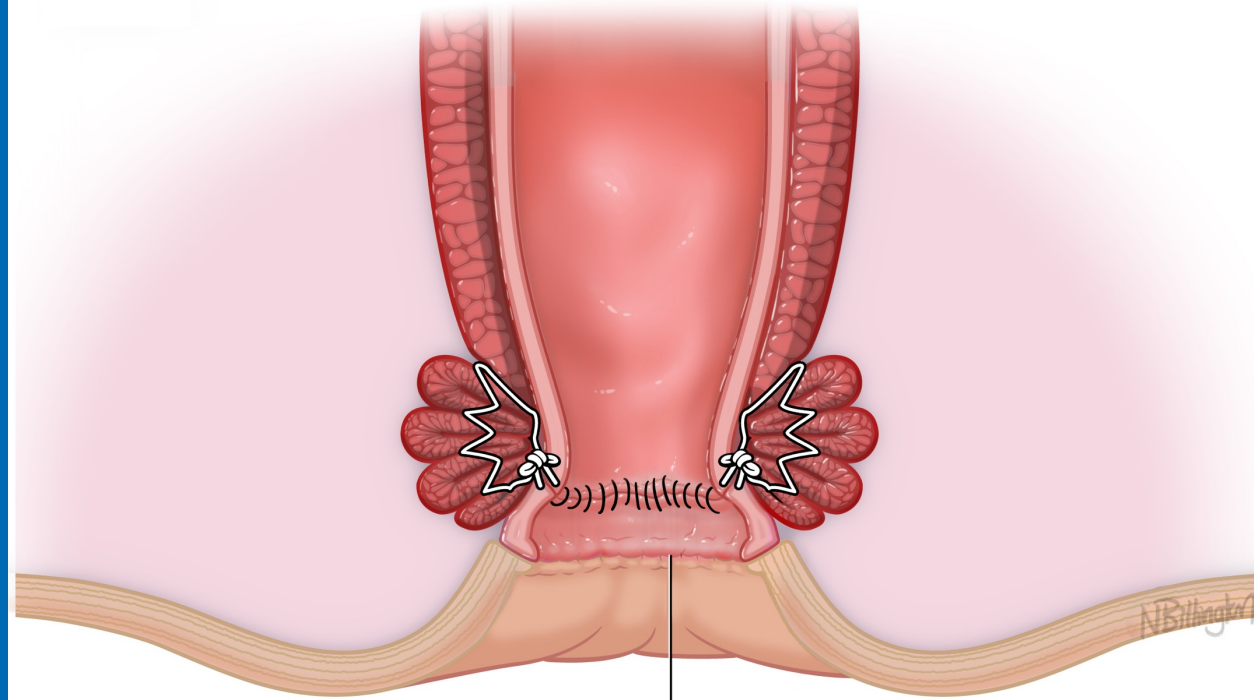


-  Mucosa
-  Muscularis
-  Skin
-  Line of final anastomosis



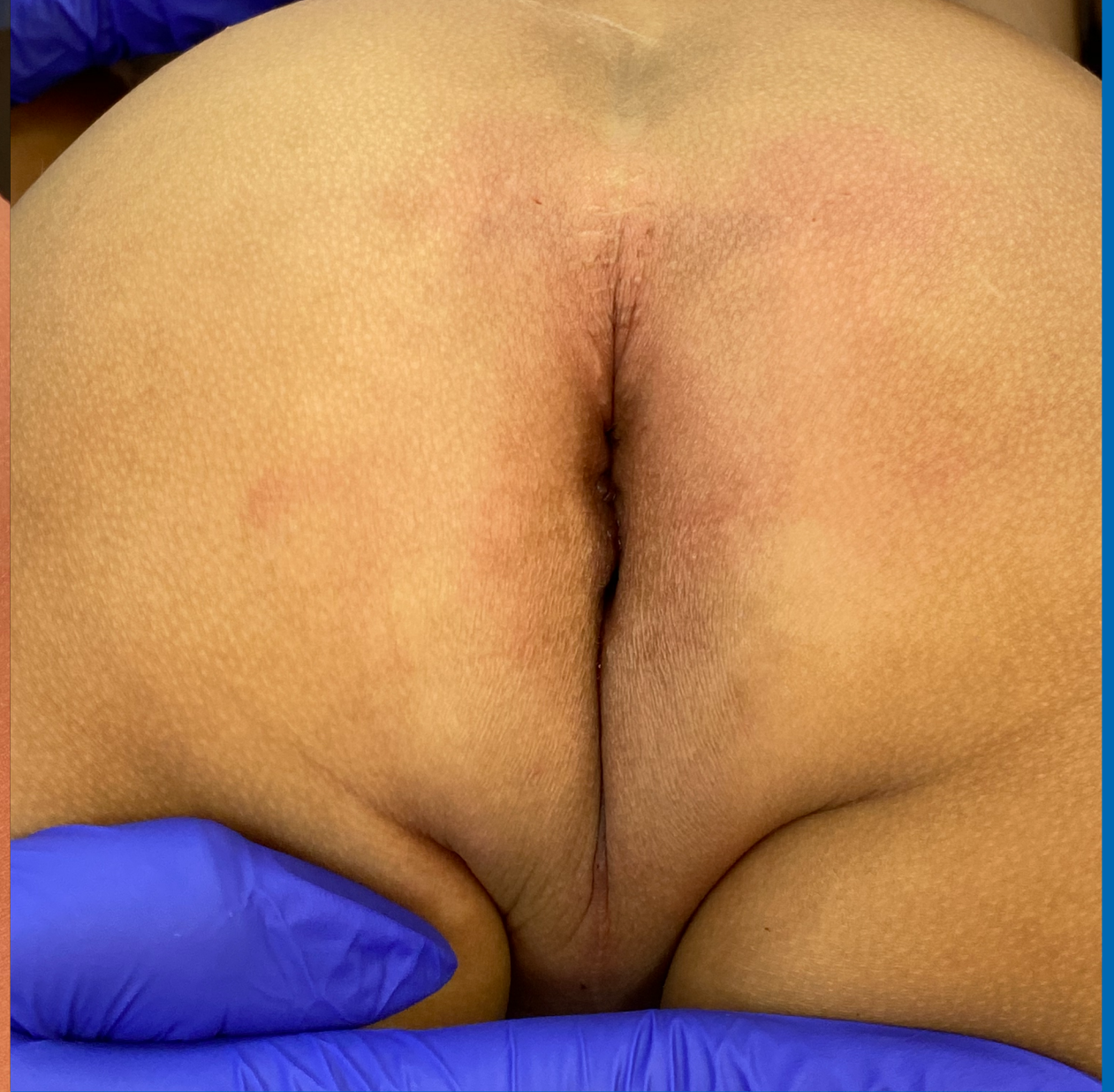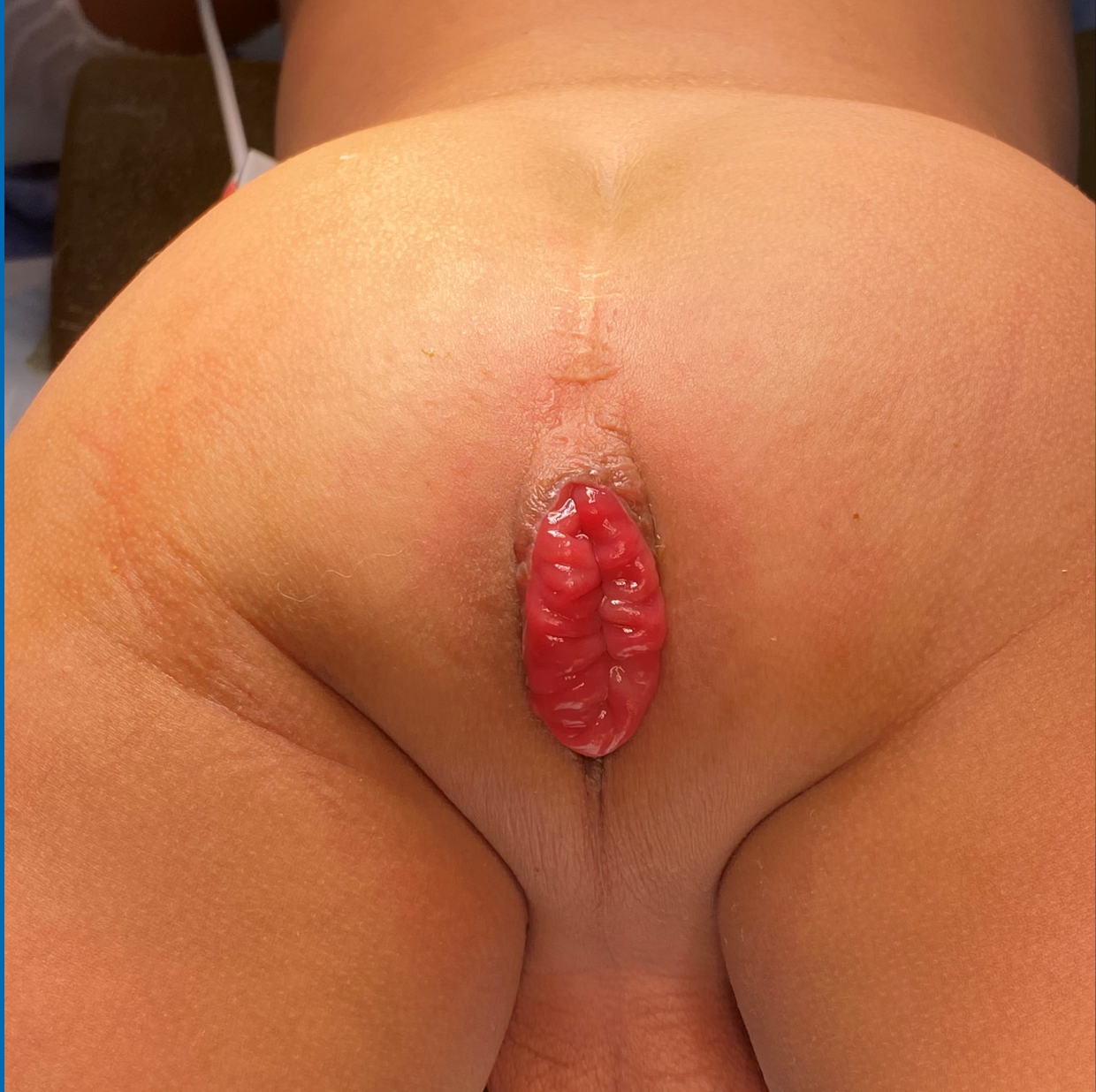Children's Hospital Colorado
Here, it's different.™

INTERNATIONAL CENTER FOR
**COLORECTAL AND
UROGENITAL CARE**



MC

- Mucosa
- Muscularis
- Skin



Children's Hospital Colorado
Here, it's different.™

INTERNATIONAL CENTER FOR
**COLORECTAL AND
UROGENITAL CARE**